ANEMİLER, RİSKLİ GRUPLAR, TANI VE TEDAVİ YAKLAŞIMI

Dr. Osman Yokuş

İstanbul EAH, Hematoloji Kliniği,Fatih, İSTANBUL

16-18 Mayıs 2015

Önce Hasta Anemik mi?

- RBC sayım
- HB seviye
- Hct seviye
- Volume durumu

Aneminin Tanımı(1)

- Anemi Hgb normalin altı olması
- Erkekte Hct %37, kadında %34 altı;
  yada erkek hgb; 12,5 altı, kadında; 11,5 altı
- Çocukluk yaşa göre anemi eşiği değişir
- MCV'ye göre (kabaca) sınıflanır

ANEMI TANIMI(2)

- Yaş ve cinse göre Hb seviyesinin normal altı olması
  Erişkinlerde:
- DSÖ kriteri: Hgb kadında 12 gr/dl erkekte 13gr/dl altı
- Fakat hgb, Hct ve eritrosit şunlara göre değişebilir
  - Cins/yaş
  - ırk
  - Yükselti
  - Sosyoekonomik durum değişimi
  - Referans aralık göz önünde bulundur

Eritropoez için gerekli faktörler

- 1. Eritropoietin
- 2. Fe
- 3. Vitamin B_{12} (siyanokobalamin)
- 4. Folik Acid (folat)
- 5. Ascorbik asid (Vitamin C)
- 6. Piridoksin (Vitamin B_6)
- 7. Aminoasit

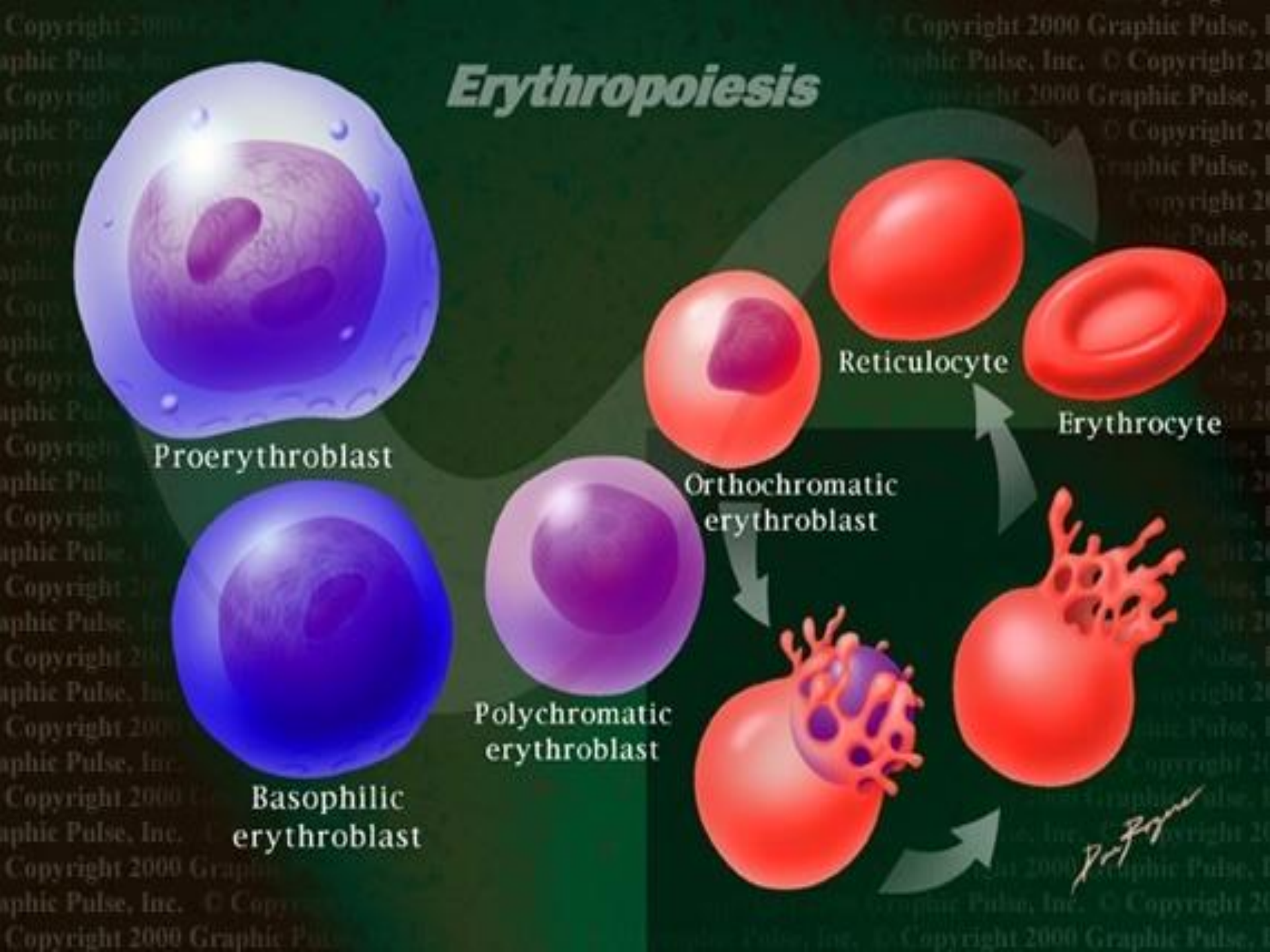
Erythropoiesis
Proerythroblast
Basophilic erythroblast
Polychromatic erythroblast
Orthochromatic erythroblast
Reticulocyte
Erythrocyte

Kırmızı Küre Üretimi

EPO

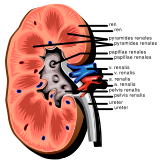

Renal Doku O2 Algılayıcı

KK Üretim Döngüsü

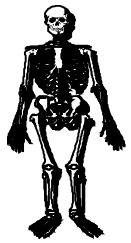

Kemik İliği

Retikülosit

Olgun Kırmızı Küre

Age and blood count changes

age	WBC	Neutrophyls	Eos.	Baso	Lenfo	Mono	Hb
12 mo	6-17.5	1.5-8.5	0.05-0.7	0-0.20	4-10.5	0.05-1.1	11.1-14.1
4 y	5.5-15	1.5-8.5	0.02-0.65	0-0.20	2-8	0-0.8	11.2-14.3
6 y	5-14.5	1.5-8	0-0.65	0-0.20	1.5-7	0-0.8	11.4-14.5
10 y	4.5-13	1.8-8	0-0.60	0-0.20	1.5-6.5	0-0.8	11.8-15
21 y	4.5-11	1.8-7.7	0-0.45	0-0.20	1-4.8	0-0.8	E: 16 K: 14

WBC: x10E3/mm^3 Hb:g/dL

Anemi ise hangi çeşit anemi var?

- Hikaye, Fizik muayene
- RBC,HB,Hct ,
- MCV, MCH,RDW
- Eritrosit morfolojisi nasıl (PY)
- Retikülosit sayım sonucu ne?
  - Artmışmı?
- Diğer labor. sonuçları nasıl?

ANEMI SINIFLANDIRMA

A. Relatif/Mutlak
B. İzole/Diğer dizilerde değişiklikler
C. Kalıtsal/Edinsel
D. Gelişim hızına göre

I. Akut (hemoraji, hemoliz)
II. Kronik (diğerleri)

En sık rastlanan anemi türleri

- Demir eksikliğine bağlı anemi
- Folik asit eksikliğine bağlı anemi
- Vitamin B-12 eksikliği anemisi

SINIFLANDIRMA(2)

Oluşum mekanizmasına göre

I. Kan kaybına bağlı
II. Kemik iliğinde yapım azlığına/bozukluğuna bağlı
III. Kemik iliği dışında yıkım/tutulum artışına bağlı

Eritrosit indekslerine göre

Mikrositik, normositik, makrositik

FARKLI HASTALIKLARDA ANEMI'NIN FARKLI YORUMU

- **Anemi değer öncesi plazma volüm değişimi varmı düşün!
  - Volum konsante: anemi yok zanedilir
  - Volume fazla: hb seviye yalancı düşük çıkar

** KOAH gibi durumda hgb normal çıksa da anemi atlanmamalı .

**Talasemi gibi bazı özel hastalıklarda kan değerleri anemi gibi görülse de eritrositler yeterlidir. (örn:Thalassemia trait)

Örn: Hb düşük, RBC artmış, MCV düşük

Hb: 10 g/dL (anemi)

RBC: 6.5 million/mm3 (eritrositoz)

MVC : 70 fL

LABARATUAR(1)

- Tam kan sayımı,MCV,RDW
- Ferritin, vit B12,TSH, sedim yada CRP
- Biyokimya: üre, LDH, bilurubinler
- Retikülosit
- Periferik yayma
- Ön tanıya uygun çeşitli testler
  - Hb elektroforezi,direkt coombs testi,G6PD düzeyi gibi
- Nadiren Kemik iliği aspirasyonu gerekebilir

Anemiyle ilgili Lab. tetkikleri (2)

- Eritrosit enzimleri
- Hb F,A2,Hb elektroforez
- Coombs testleri
- KC, böbrek, endokrin, fonksiyon testleri
- İdrar tetkik
  - Hemosiderin
- GİS gizli kan test / parazitler

(*testler kişiye göre seçilir /rutin değildir*)

Anemlerinin eritrosit büyüklüğüne göre sınıflaması

I.Mikrositik anemiler

Demir eksikliği anemisi
Talasemi sendromları
Kronik kurşun zehirlenmesi
Kronik inflamasyon
Sideroblastik anemi(nadir)

II.Makrositik anemiler

1.Megaloblastik olan:

-B12 eksikliği
-Folik asit eksikliği
-Herediter orotik asidüri

2.Megaloblastik olmayan:

-Aplastik anemi
-Diamond-Blackfan anemisi
-Hipotiroidi
-Karaciğer hastalığı
Diseritropoetik anemiler

III.Normositik anemiler

1.Konjenital hemolitik anemiler

-Bazi hemoglobinopatiler
-Enzim eksiklikleri
-Eritrosit membran bozuklukları

2.Edinsel hemolitik anemiler

-Antikora bağlı
-Mikroanjiyopatik hemolitik anemi
-Akut infeksiyona bağlı
-Akut kan kaybı
-Kronik böbrek hastalığı

Mikrositik hipokromik anemi araştırması

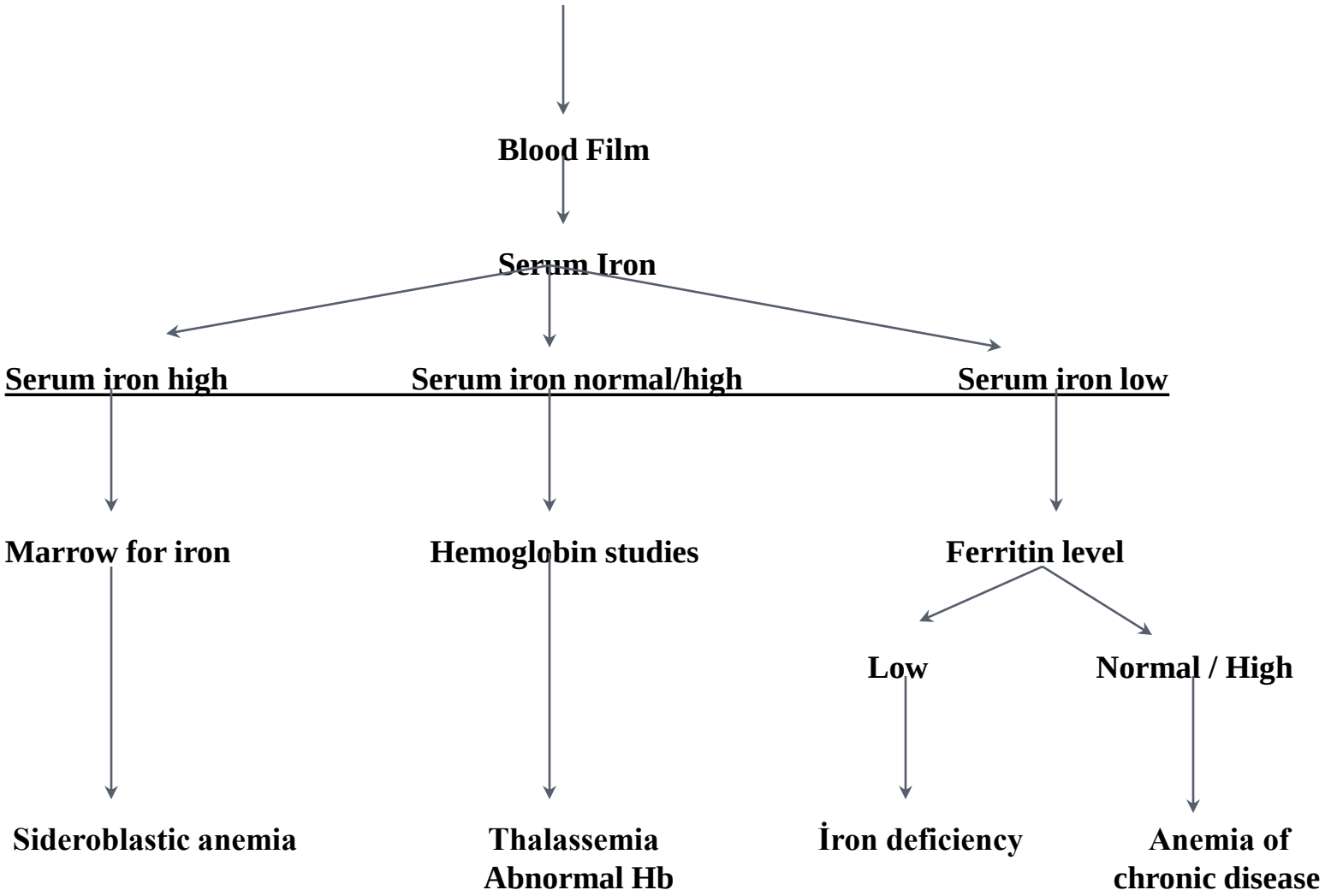

Demir eksikliği anemisi

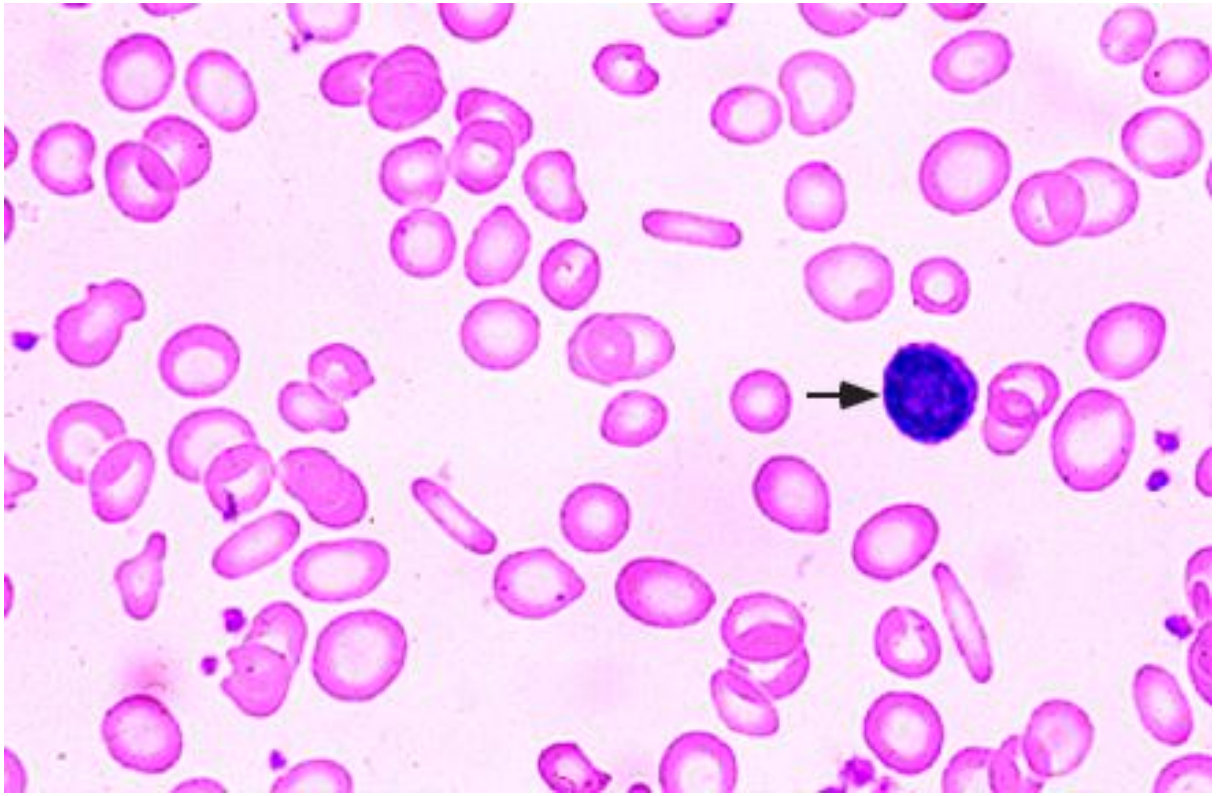

Talasemi, (PY)

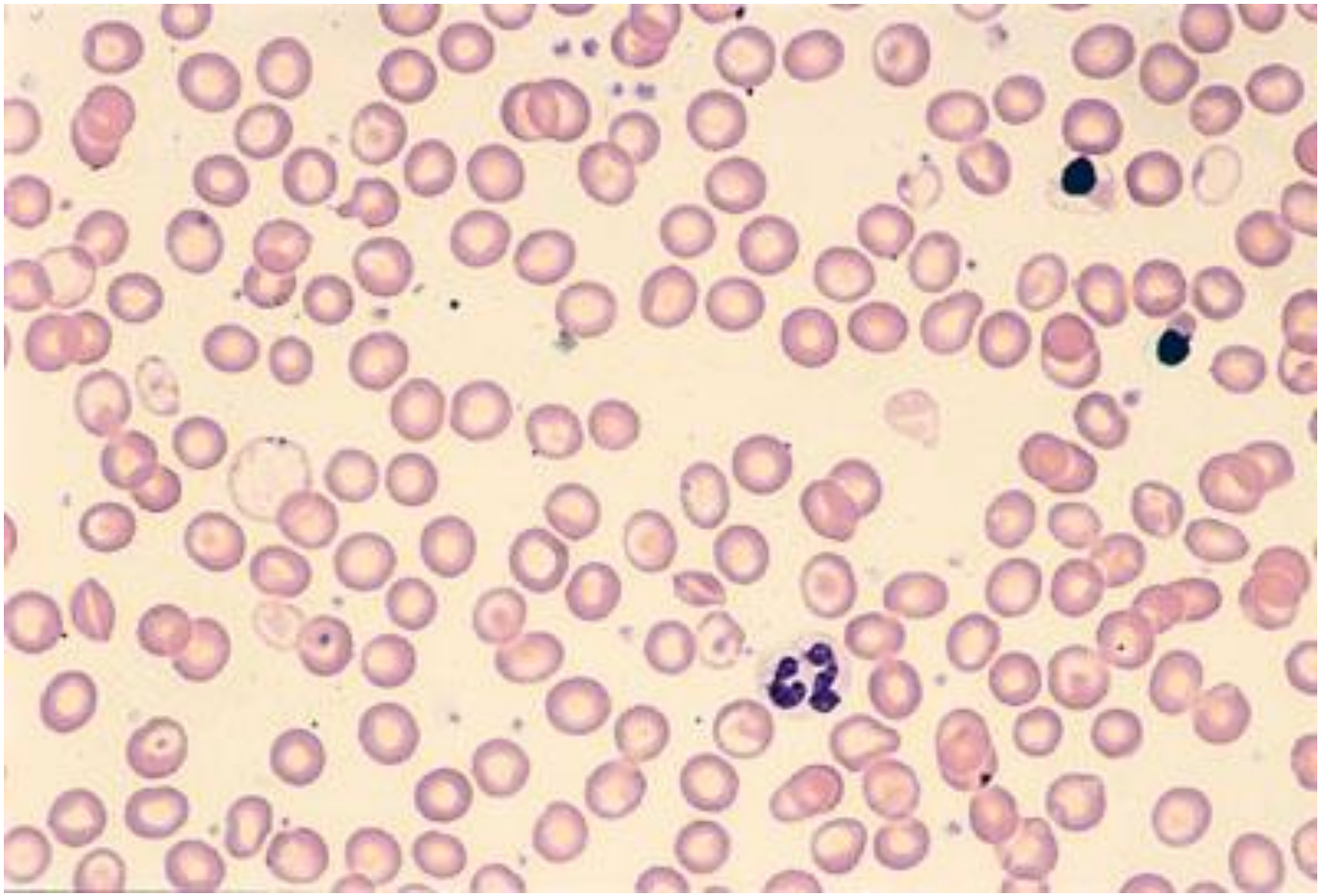

DEA – (Kaşık tırnak) koilonychia

Normositik normokromik anemi araştırması

Reticulocyte count

Retic. normal / low

Retic. high

response to anemia treatment

hemolysis

acute blood loss

Bone marrow morphology

Normal

Abnormal

Hypoplastic

infiltration

dysplastic

Secondary anemia

eg. Inflammation

liver disease

Renal failure

endocrine failure

aplastic anemia

leukemia

myelofibrosis

metastases

myelodysplasia

Normal Periferik yayma

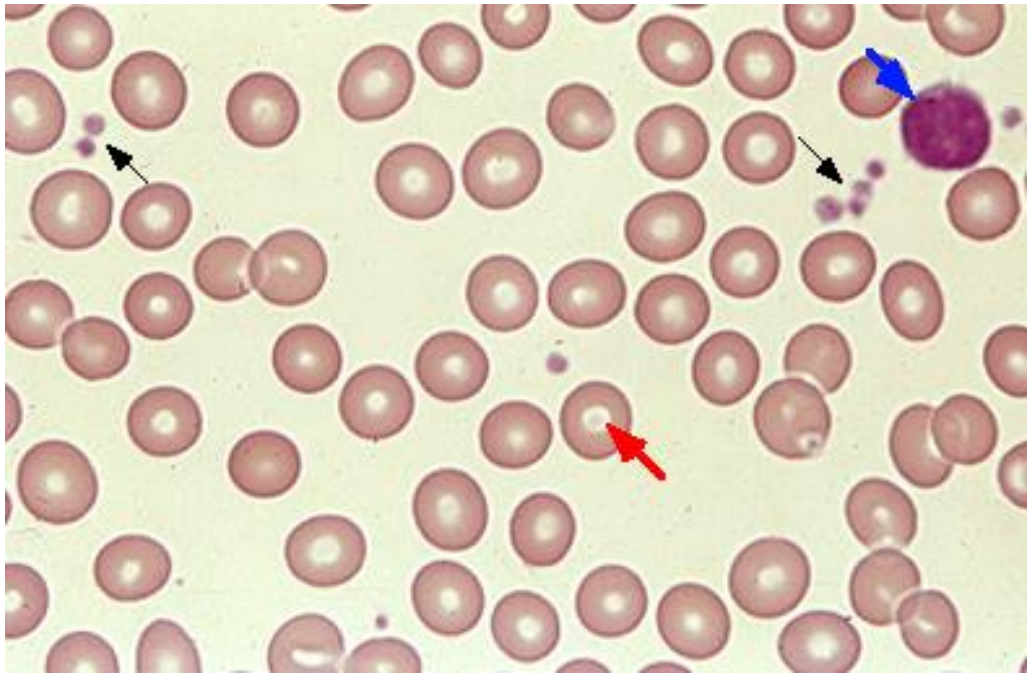

Orak Hücreli Anemi

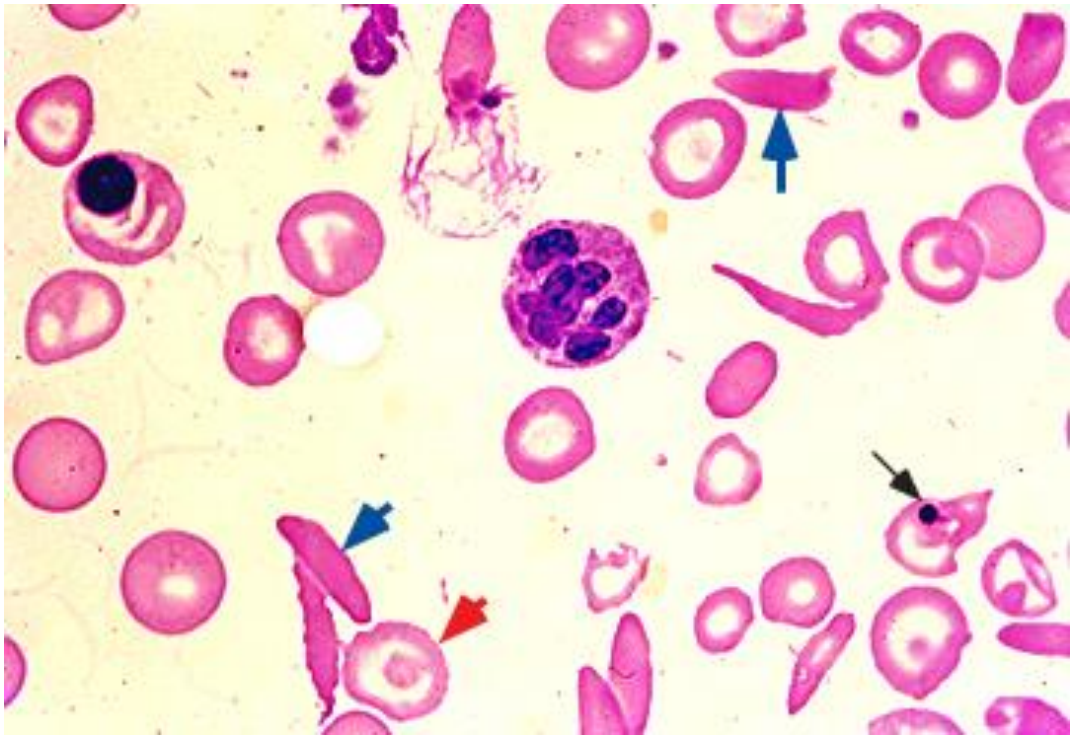

Makrositik anemi (MCV: yüksek)

Blood film

Reticulocyte count

Retic. High

Acute blood loss or

Hemolytic anemia

Treatment response

Retic. Normal/low

Bone marrow

Non-megaloblastic

normoblastic

(Other macrocytic anemias)

dysplastic(MDS)

Megaloblastic

folate or B12 levels

folate deficiency

Vit B12 deficiency

Vitamin B12 Eksikliği (PY)

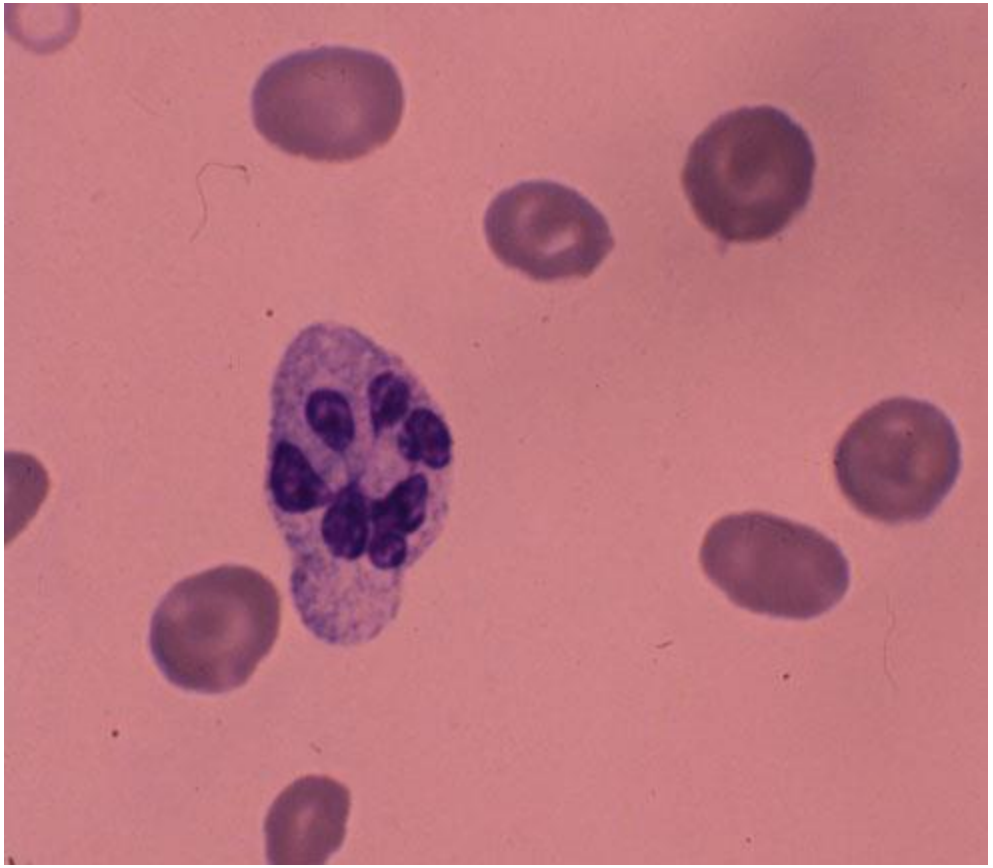

Folat Eksikliği

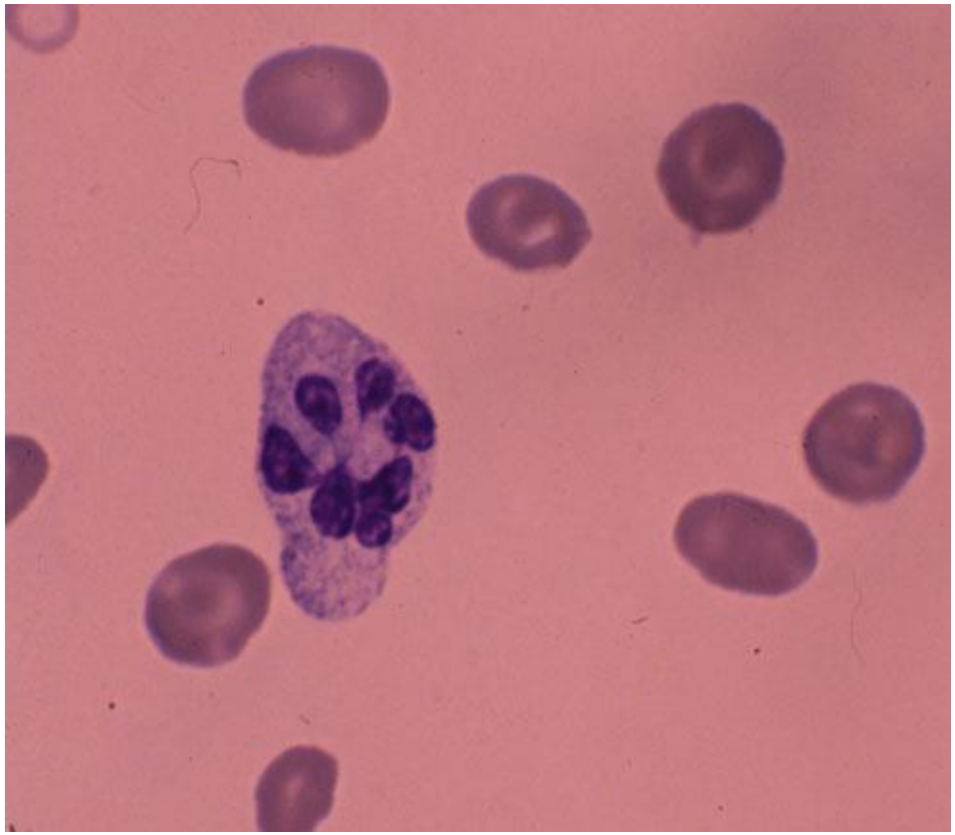

Hikaye ve fizik muayene

- Semptom süresi (akut/ gizli)
- Kanama varmı? Burun/cilt/üriner/dışkı gibi..
- Aile hikayesi
  - Anemi, safra taşı ve splenektomi
  - Kanama hastalığı
- Meslek, hobi, seyhat,(toksik, infeksiyon geçişi/temas varmı)
- Cilt saç tırnak değişimi varmı sor

TANI VE ARAŞTIRMA

- Hasta anemik mi?
- Anemi ise tipi ne?
- Anemi nedeni ne?

ANEMİ SINIFLAMASI

- Morfolojik
  - Normositik: MCV= 80-100fL
  - Makrositik: MCV > 100 fL
  - Mikrositik : MCV < 80 fL
- Patojenik (altta yatan mekanizma)
  - Kan kaybı (kanama)
  - RBC üretim azalışı
  - RBC parçalanma artışı/göllenme

Normositik Anemiler

- Akut posthemorajik anemi
- Hemolitik anemi (talasemi ve bazı hgb hastalıları hariç)
- Aplasti anemi
- Pure red cell aplazi
- Kemik iliği infiltrasyonu
- Endokrin hastalıklar
- Renal yetersizlik
- Karaciğer hasta.
- Kronik hasta anemi
- Protein malnutrisyonu
- C vit azlığı

Mikrositik Anemiler

- DEA
- Talasemi
- Sideroblastik anemi
- Kurşun zehirlenmesi
- Kronik hastalık anemileri

Makrositik anemiler

- Megaloblastik

- Non-megaloblastik

Megaloblastik Makrositik Anemi:

- Vit B12 eksikliği
- Folik asid eksikliği
- Diğer

Non-megaloblastik Makrositik Anemi

- Akut kanama anemileri
- Hemolytik anemiler
- Lösemiler

(örn: akut)

- Myelodisplastik sendromlar
- Karaciğer hastalıkları
- Aplastik anemi
- Kemik ilik infiltratif hastalıkları
- Alkolizm
- Hipotiroidizm
- Açlık

Patojenik sınıflama (Anemi nedenleri)

- Rölatif (plazma volüm artışı)
- Decreased RBC üretim azalışı
- Kan kaybı
  - Akut kanamaya bağlı anemi
- RBC hasarı artışı

Patojenik sınıflama (Anemi nedenleri)

- Azalmış Hgb üretimi
  - Defektif DNA sentezi
  - Kök hücre defekti
    - Pluripotent kök hücre
    - Erythroid kök hücre (progenitors)
  - Diğer daha az tanımlı anemiler
- Kan kaybı
  - Akut kanamaya bağlı anemi
- Artmış RBC parçalanmasına bağlı anemi
- Rölatif (artmış plazma volumü)

Azalmış Hb üretimi

- DEA
- Talasemi
- Sideroblastik anemi
- Kurşun zehirlenmesi

Defektif DNA sentezi

- Vit B12 eksikliği
- Folic asid eksikliği
- Diğer

PLURİPOTENT KÖK HÜCRE DEFEKTİ

- Aplastik anemi
- Lösemi veya MDS

Defektif eritroid kök hücre

- Pure red cell aplazi
- Kronik böbrek yetersizliğine bağlı anemi
- Endokrin hastalıklara bağlı anemi
- Konjenital dyserythropoetic anemi

Multipil veya tam anlaşılamamış mekanizma ile gelişen, azalmış RBC üretimi olan anemiler

- Kronik hastalık anemisi
- Kemik iliği infiltrasyonu
- Nutrisyonel eksikliklere bağlı anemi

Artmış RBC parçalanması ile giden anemiler (hemolitik anemiler)

Şöyle sınıflanır

- Hücre içi defektlere bağlı hemoliz (parçalanma)
- Hücre dışı defektlere bağlı hemoliz
- Herediter hemolitik hastalıklar
- Kazanılmış hemolitik hastalıklar
- Intravasküler hemoliz
- Ekstravasküler hemoliz

Hemolitik Anemilerin basit sınıflaması

Hücre içi

1- RBC içi anomaliler

a. Enzime defektleri

b. Hemoglobinopatiler & Talasemiler

2-RBC membran anomaliler

a. Hereditaer sferositoz, eliptositoz

b. Paroksismal nokturnal hemoglobinuri

Herediter

c. Spur cell anemi

Hücre dışı

3- Dış faktörler

a. Hipersplenizm

b. Antikor : immun hemoliz

c. Travmatik & Mikroanjiopatik hemoliz

d. Infeksiyon , toksinler

Kazanılmış

Sferositoz

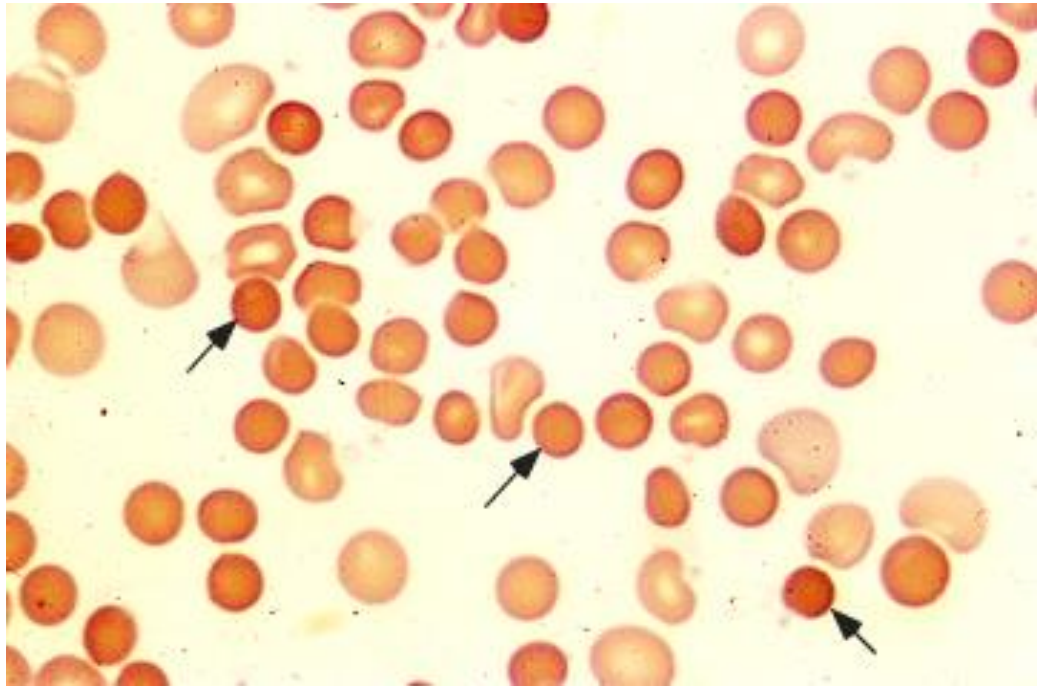

TTP / HUS – MIKROANJIYOPATIK HEMOLITIK ANEMI (ŞISTOSITLER GÖRÜLMEKTE)

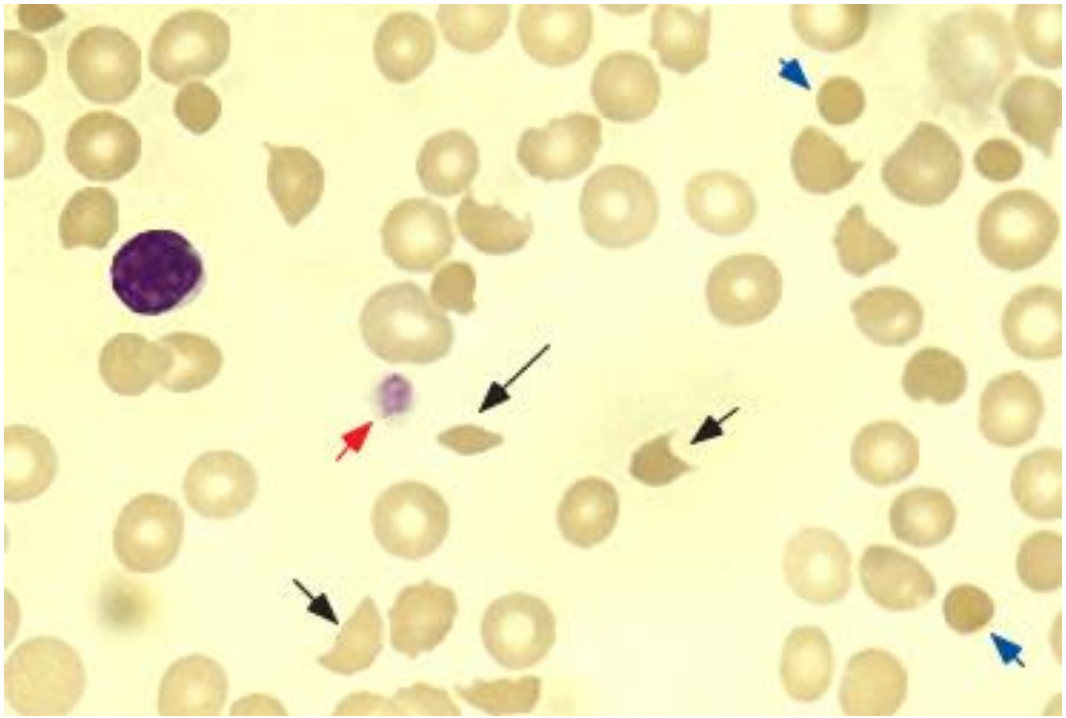

Malaria

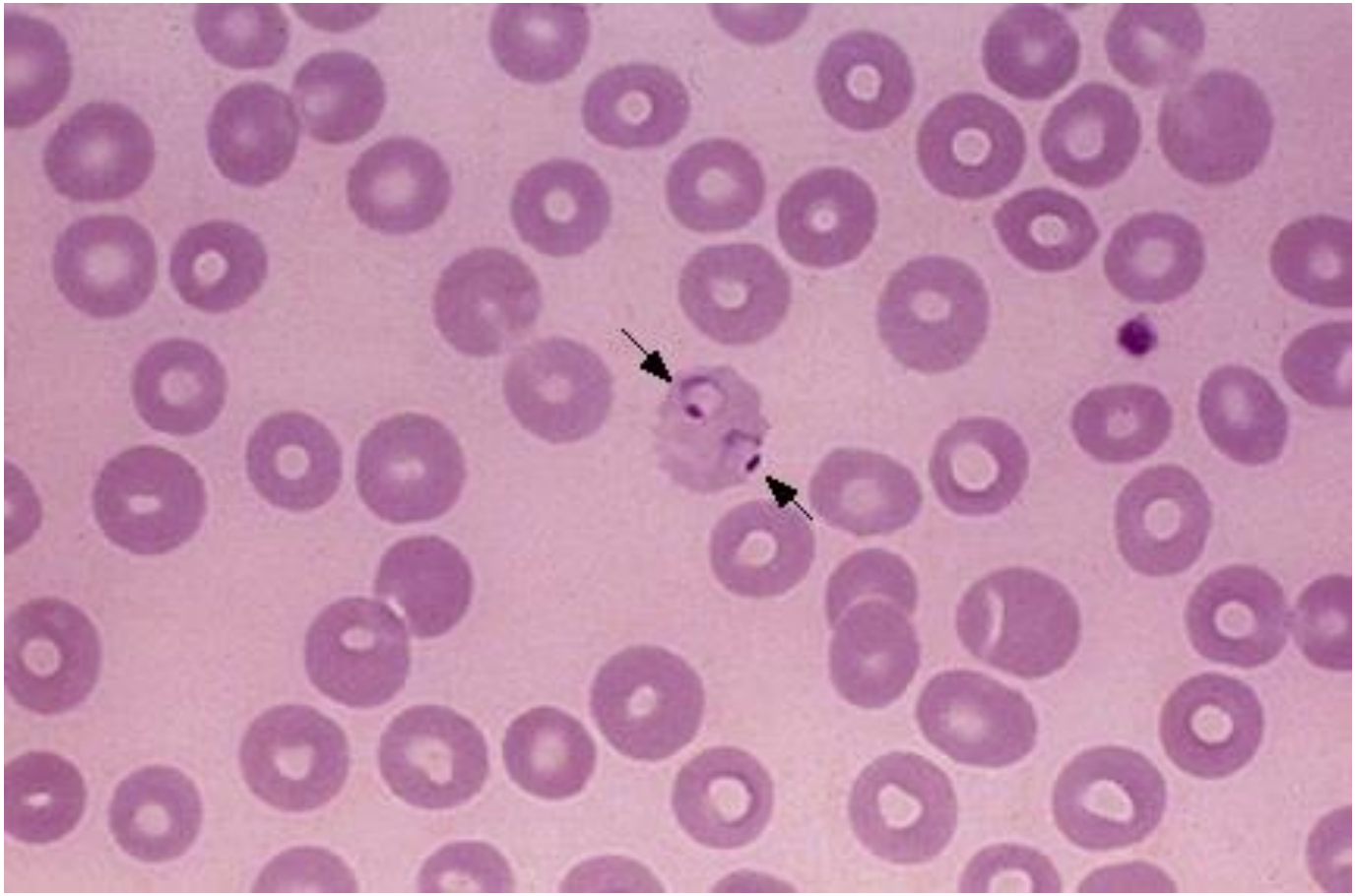

Babesiosis

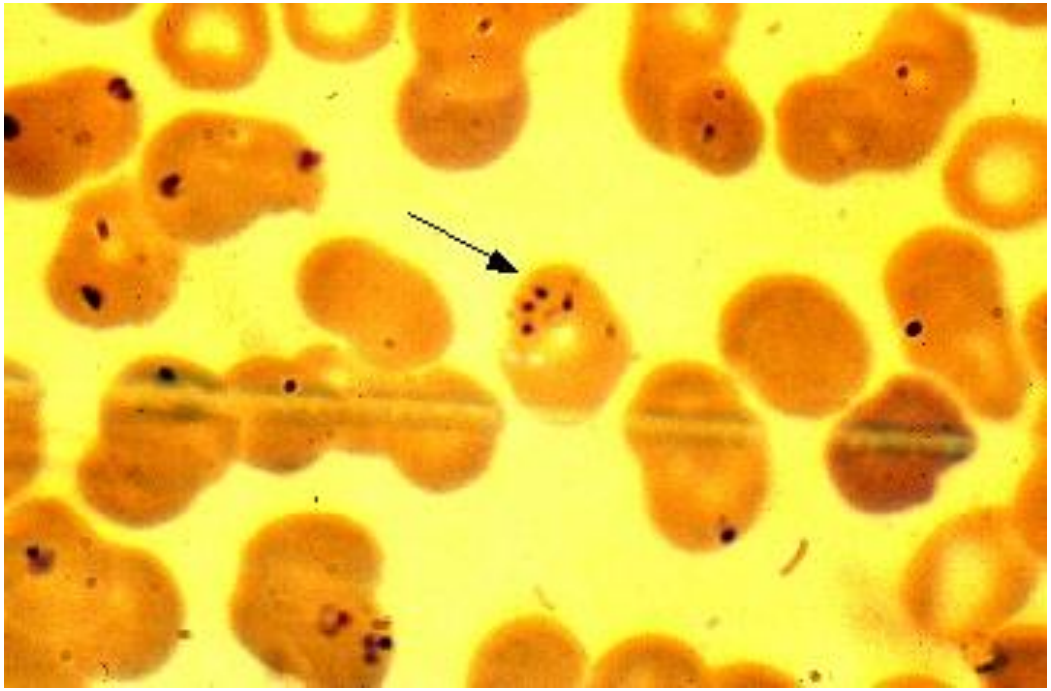

Olgu(1)

- A 41-yaş erk. HIV(+), CD4 : 150 Hgb:11, Hct; 33, daha önce ise Hgb ; 14 ve Hct :42.
- Melena v.s yok(kanayan yok)
- Cilt sararma yok
- Ateş, bulantı kusma yok
- HIV/AIDS
  - Özgeç anemi herediter anemi nedenleri yok
- Allerji; Sulfa
- İlaç:
  - Efavirenz
  - Emtricitabine
  - Tenofovir
  - Dapsone
- Sosyoal öykü:
  - Syhat yok, hasta ile temas yok, yalnız yaşıyo, nadir alkol alımı iv ilaç almıyor
- Aile öykü:
  - Ailede kanser öykü yok

OLGU(1),DEVAM

- Ateş:37.8, TA: 123/68
- Genel durum iyi
- sklerada sarılık yok, LAP yok.
- Sistem muayeneleri normal

OLGU# 1 (DEVAM)

- LAB:
  - WBC: 4.3
  - Hgb: 11
  - Hct: 33
  - Platelet: 224
  - Sodium: 137
  - Potassium: 3.8
  - Chloride: 101
  - CO2: 25
  - Glukoz: 102
  - Tot. Protein: 5.3
  - Albumin: 3.1
  - Total Bili: 1.4
  - Dir. Bili: 0.2
  - AST: 23
  - ALT: 42
  - Alk. Fosf: 122
  - Haptoglobin: 20
  - Retikülosit sayım: %3.2

Hangi ilave laborat. test istersiniz?
Eğer bilurubin artmış olsa ve platelet azalmış olsa PY da neyi görmeyi beklersiniz.?

Demir Eksikliği Anemisi

- Düşük miktarda demire bağlı olarak kanın kırmızı hücrelerindeki azalmadır.
- Aneminin en sık nedeni
- Demir eksikliğinin nedenleri :
  - *Diyette*
  - *az miktarda emilimi*
  - *kanamalar*
- Yüksek risk grubu
  - Doğurganlık çağı kadın (adet , doğum)
  - Çocuklar ve diyet eksik olanlar.
  - *Yiyecek dışındaki şeylere istek (PİKA). Örneğin: toprak, buz, kireç taşı, nişasta gibi…*
  - *Ağız kenarında ve tırnaklarda çatlaklar*
  - *Tırnaklarda biçimsizlik: kaşık biçimi almaları gibi…*
  - *Tahriş olmuş dil*
  - Günlük demir:1-3 mgr. lazım

  - Fe zengin Besinler:Kırmızı et, karaciğer, balık, kuru üzüm ve yumurta sarısı demir açısından zengin gıdalardır.

Demir Eksikliği Anemisinde Tedavi

- Demir eksikliği tüm yaş gruplarında özellikle 6-24 aylar arasında ve büyümenin hızlandığı dönemlerde daha sık görülmekte
- En sık kullanılan tedavi biçimi günde 3 mg/kg elementel demirin ağızdan, yemeklerden en az yarım saat önce alınmasıdır.
- İki yaştan küçük bebeklere sabah kahvaltısından yarım saat önce tek doz ; iki yaşından büyük çocuklarda 2-3 doz biçiminde yemeklerden önce verilir
- Erişkinlerde 4 ay süreli günde 1-2 defa –yemek 2 saat önce - demir tedavisi verilir
- Tedavi ile 1-2 ayda hg de 1-3 gr Hct ‘de %3-6 artış beklenir.
- Ağır anemide bir-iki hafta içinde retikülositoz yanıtı görülür

DEA

- DEA tedavisinde nedene yönelik önlemler alınmalı,
- Demirden zengin besinlerin kullanılması, demir emilimini bozan süt, çay ve kepekli gıdaların demir preparatları ile birlikte alınmaması, C vitamininden zengin portakal suyu gibi emilimi arttırıcı besinlerle verilmesi sağlanmalıdır

Fe tedavisine yanıt yoksa

- 1. Tedaviye uyumsuzluk ya da ilacın yanlış kullanımı,
  2. Aktif Kan kaybı
  3. Tedavi süresi az
  4. Mide pH'sını yükselten ilaçların kullanımı,
  5.kombine anemiler
  6. Yanlış tanı.

Demir Eksikliği Anemisinden Korunma

*Prematüre ve düşük doğum ağırlıklı bebeklerin demir depoları term doğan bebeklerden daha düşük, büyümeleri ise daha hızlıdır. Demir depoları erken tükeneceği için bu bebeklerde anne sütüyle beslenmeye iki ya da üçüncü ayda demir eklenmelidir.

*Ek gıdalara başlandığında ise kesinlikle demir yönünden zengin besinlerde verilmelidir.

DEA YAŞLARA GÖRE NEDENLERI

- *Ergenlik döneminde (12-18 yaş) hızlı büyümenin yanında özellikle genç kızlarda menstrüasyonla kan kaybı, vejeteryan ve semivejeteryan beslenme biçimi, yetersiz besin alımı, zayıflama rejimleri, yeme bozuklukları (anoreksia nervosa vb.) demir eksikliğinin sık görülmesine neden olmaktadır.
- Oyun çocukluğu döneminde (bir-üç yaş) ana sorun aşırı süt tüketimidir. "Milkakolik sendrom" da denilir; günde 500 ml den fazla süt tüketilmemelidir
- *Okul öncesi (4-7 yaş) ve okul çocukluğu (7-12 yaş) döneminde demir eksikliği anemisi az dır.
- Okul çocukluğu dönemindeki çocuklarda daha çok beslenme hataları dışındaki nedenler; mide barsak hastalıkları düşün ve tedaviye ilk 2 ayda yanıt yoksa detaylı tetkik gerekir
- Erişkinlerde ise 50 yaş üzeri ve altı ve kadın ve erkekte farklı yol izlenir…

a)
(b)

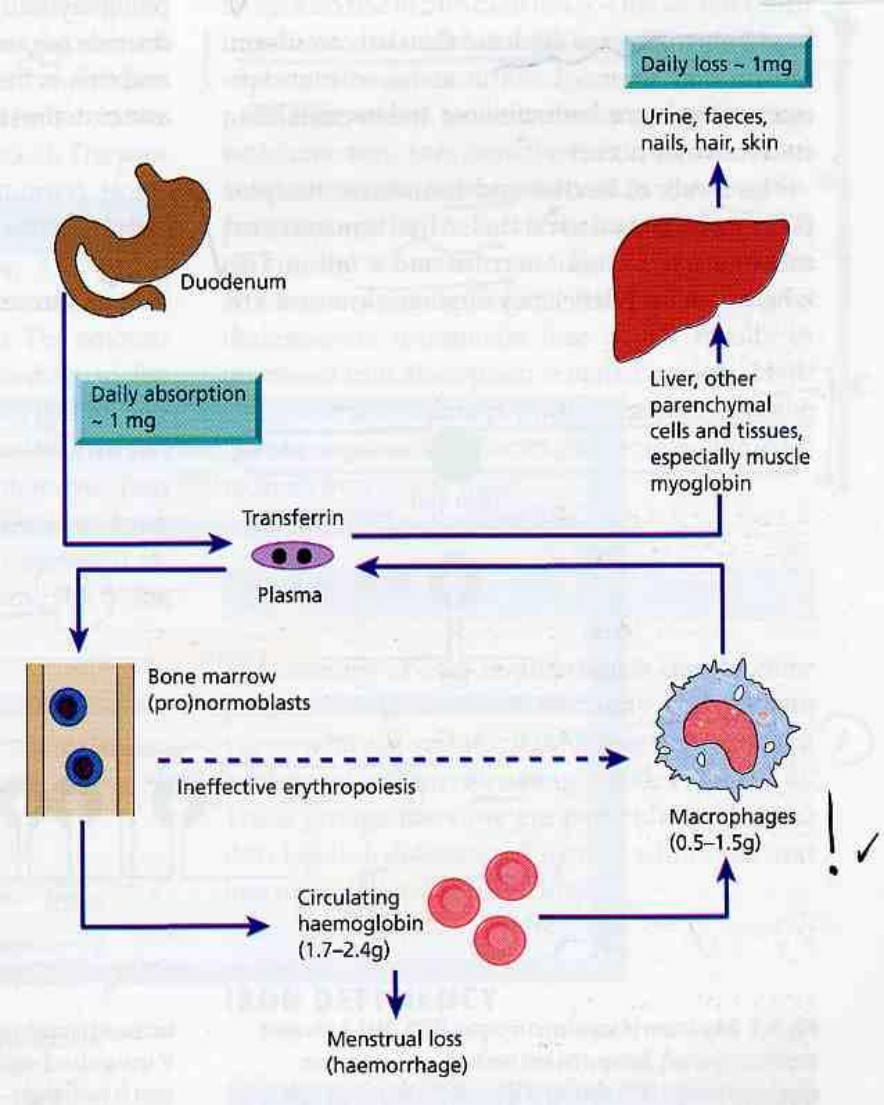
Daily loss ~ 1mg
Urine, faeces, nails, hair, skin
Duodenum
Daily absorption ~ 1 mg
Liver, other parenchymal cells and tissues, especially muscle myoglobin
Transferrin
Plasma
Bone marrow (pro)normoblasts
Ineffective erythropoiesis
Macrophages (0.5–1.5g)
Circulating haemoglobin (1.7–2.4g)
Menstrual loss (haemorrhage)

Kan Kaybı

- Erişkin hastalarda > çocukluk yaş grubu
  - mide ülseri
  - barsak kanserleri
  - NSAID kullanımı
- Çocuklarda inek sütü verilmesi
  - inek sütü ile yapılan mamalar nedeni ile sıklıkla demir eksikliği gelişmektedir.
  - İnek sütünde demir içeriği azdır ve barsaklardan kanamaya da yol açar
- Barsak kurtları
  - kıl kurdu ve solucanlar demir eksikliğine yol açmaz
  - ancak kancalı kurtlar barsaklardan kanamaya neden olur
- Kanama Diatezi
  - von Willebrand hastalığı
  - Hemofili

Folik Asit Eksikliği

- **Folik Asit Eksikliğine Bağlı Anemi**
  - Folik asitin emilimini ve metabolizmasını etkileyen en önemli madde alkoldür.
  - Ayrıca keçi sütü ile beslenmekte folik asiti düşürür.
  - Bağırsak hastalıkları
  - Kanser için alınan çeşitli ilaçlar ve anti epileptikler
- **Folik Asit Eksikliğine Bağlı Aneminin kendine özgü bulguları nelerdir** ?
- *İshal*
- *Depresyon*
- *Şişmiş ve kırmızı bir dil*

Vit B12 Eksikliği

- **Vitamin B-12 Eksikliği Anemisi**
  - B-12 vitamininin emilimi mide de gerçekleşir.
- **Bu Aneminin kendine özgü bulguları ?**
  - *Eller ve ayaklarda ürperme*
  - *Bacaklarda, ayaklarda ve ellerde duyu kaybı*
  - *Sarı ve mavi renklerle ilgili olarak renk körlüğü*
  - *Şişmiş ağrıyan ve yanan bir dil*
  - *Kilo kaybı*
  - *Kararmış cilt*
  - *İshal*
  - *Düzensizlik*
  - *Depresyon*
  - *Entellektüel fonksiyonların azalması*

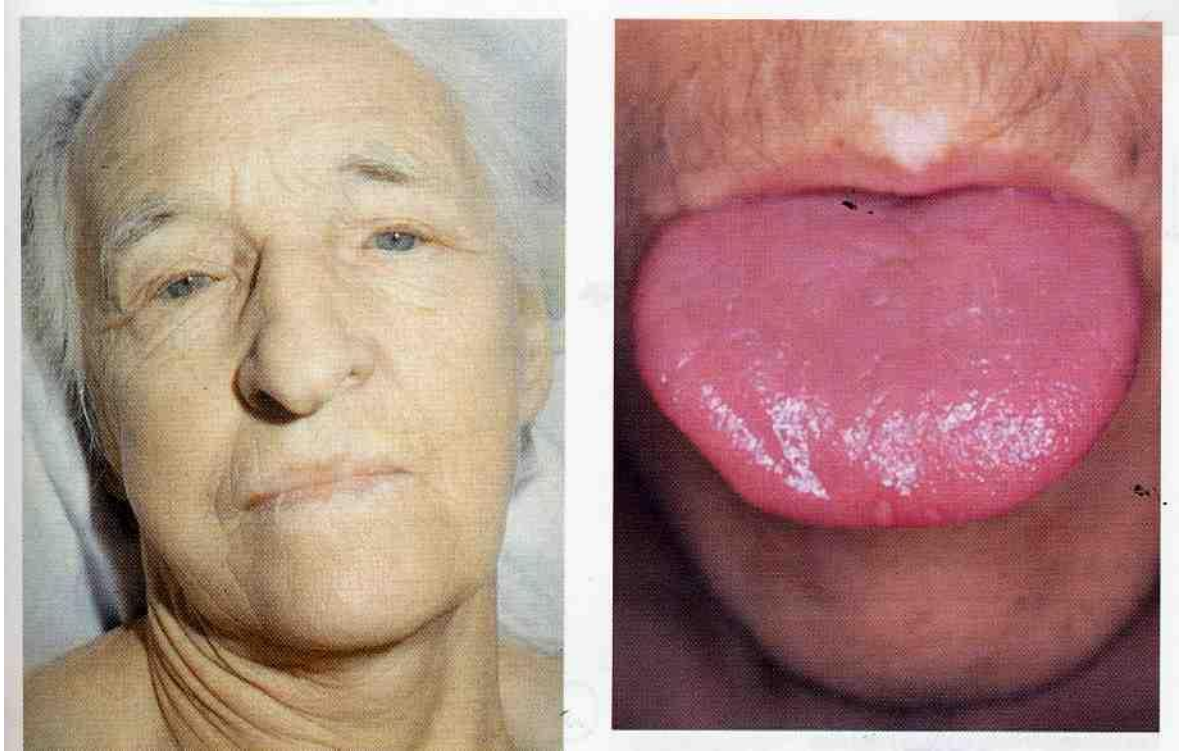

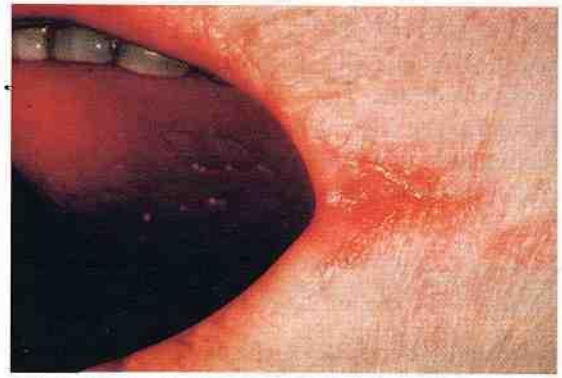

HastaNo : 10697
Yaş : 46

Kabul Tarihi : 05/02/20
Rapor Tarihi : 05/02/20

1027458
lu: 6099

Hücre Sayımları

Kırmızı Küre Değerleri

Beyaz Küre Değerleri

Test Adı		Sonuç		Birim
Tam Kan (20 panel)				
WBC sayısı		6,9		x10^3/µL
RBC sayısı		4,73		10^6cells/
PLT sayısı	*	133		x10^3/µL
Hgb miktarı		16,7		g/dL
Hematokrit (%)		46,7		%
MCV		98,6		fL
MCH	*	35,3		pg/cell
MCHC		35,8		gHb/dLErc
RDW		12,4	11,6 - 14,8	%
NE%		44,9		
LY%		44,0		
MO%		9,3		
EO%		1,6		
BA%		0,2		
NE		3,2		x10^3/µL
LY		3,0	1,5 - 4	x10^3/µL
MO		0,6	0,2 - 0,95	x10^3/µL
EO		0,1	0 - 0,7	x10^3/µL
BA		0,0	0 - 0,15	x10^3/µL
MPV		7,2		

Definitive : Thrombocytopenia
Definitive : Small Platelets
Condition : Normal WBC Pop
Condition : Normal RBC Pop
Condition : Abnormal PLT Pop

Uyarı Mesajları

Sedimantasyon	*	24	0 - 15	mm/saat

İndekslerin Yorumlanması

- OEH (MCV) klinik ve tanısal yararı en fazla olan eritrosit indeksidir.
- OEHB (MCH) genelde OEH (MCV) ile paralellik gösterir ve klinik yararı kısıtlıdır.
- OEHY (MCHC) demir eksikliği anemisinde diğer mikrositer anemilere göre daha sık olarak düşük bulunmaktadır fakat bu değişiklik geç dönemlerde ortaya çıkar.
- Artmış OEHY sıklıkla herediter siferositozda gözlenir.
- Eritrosit Dağılım Genişliği (RDW): Eritrosit dağılım eğrisinin varyasyon katsayısıdır (CV), anisositozun indirekt bir göstergesidir. Nütrisyonel anemilerde artmış olarak beklenir. Kronik hastalık anemisi ve beta talasemi taşıyıcılarında artmamıştır.
- Retikülosit Sayımı: ineffektif eritopez ve azalmış eritrosit yapımının göstergesidir.

Retikülosit Sayımı

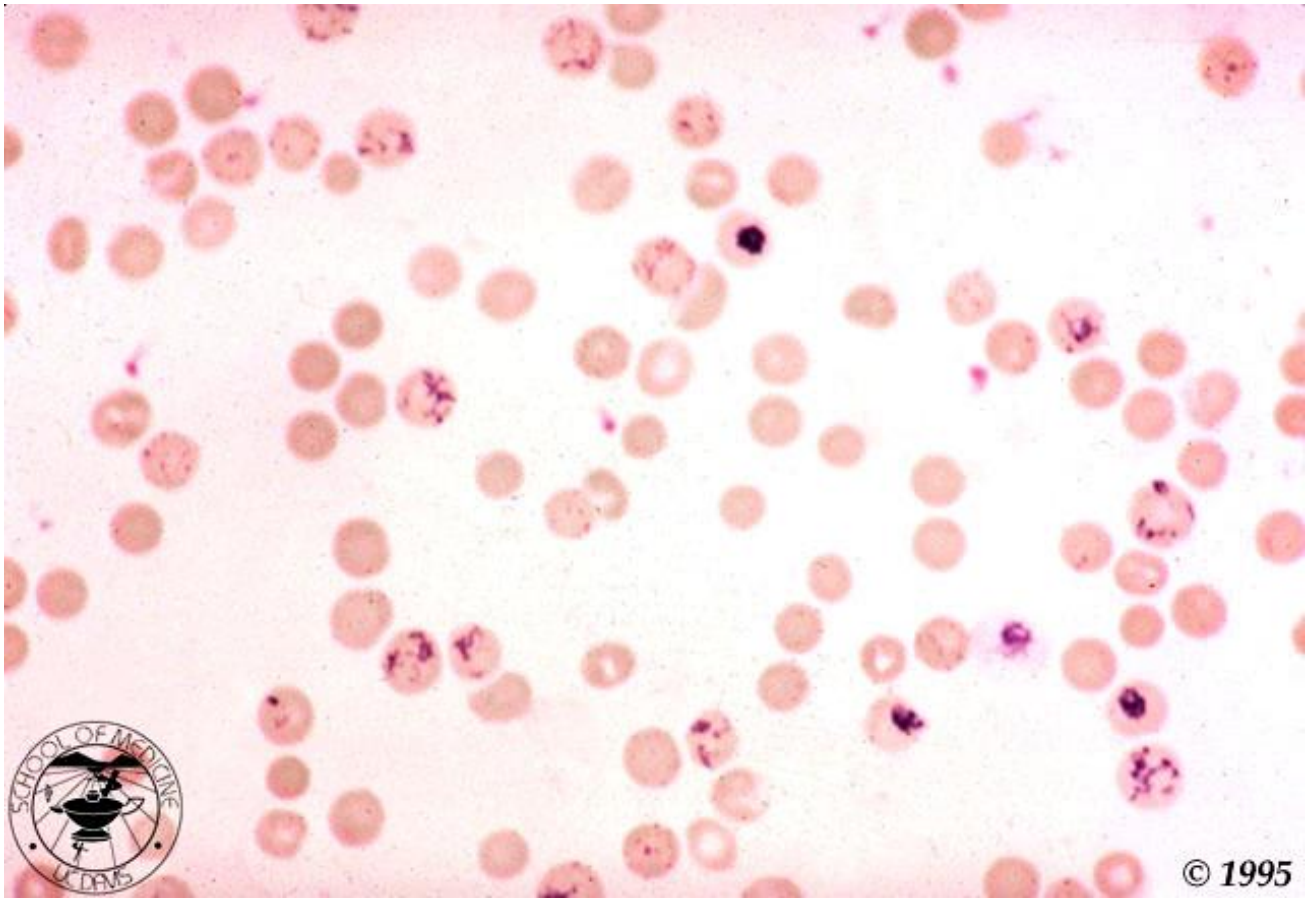

Retikülosit Sayımı (1)

- OTKSC'lerinde metilen mavisi veya flöresan RNA bağlayıcı boyalarla retikülosit sayısının mutlak değeri saptanabilmektedir
- Manuel yöntemin yetersiz düşük-normal retikülosit değerleri belirlenebilmekte
- "Mutlak retikülosit sayısı" (=%retikülosit x KKS) elde düzeltilmiş retikülosit yüzde %Ret x Htk / 45) kavramın gereksinimi ortadan kaldırmaktadır.

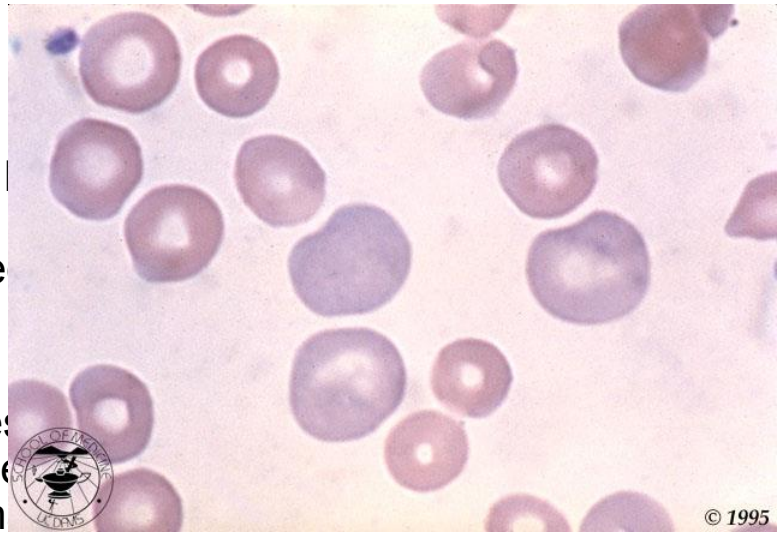

Retikülosit Sayımı (2)

- Retikülosit <80x10e9/L rejeneratif olmayan anemi
- Retikülosit >120x10e9/L rejeneratif anemi
- 80x10e9/L < Retikülosit Sayısı <120x10e9/L= gri zon

HASTALIK		ROİ
Aplastik Anemi	Düşük	Düşük
Aplastik Kriz	Düşük	Düşük/Normal
Hipoplastik Anemi	Düşük	Düşük/Yüksek
Kemik İliği Rejenerasyonu	Düşük	Düşük/Yüksek
Kronik Hastalık	Düşük/Normal	Normal
Demir Eksikliği	Düşük/Normal	Yüksek
Talasemi	Normal/Yüksek	Normal/Yüksek
Miyelodisplastik Sendromu	?	Normal/Yüksek
Folat/B12 eksikliği	Düşük/Normal	Yüksek
Hemolitik Anemi	Yüksek	Yüksek
Kan Kaybı (kanama)	Normal/Yüksek	Yüksek


SMITH, J. I
84/892

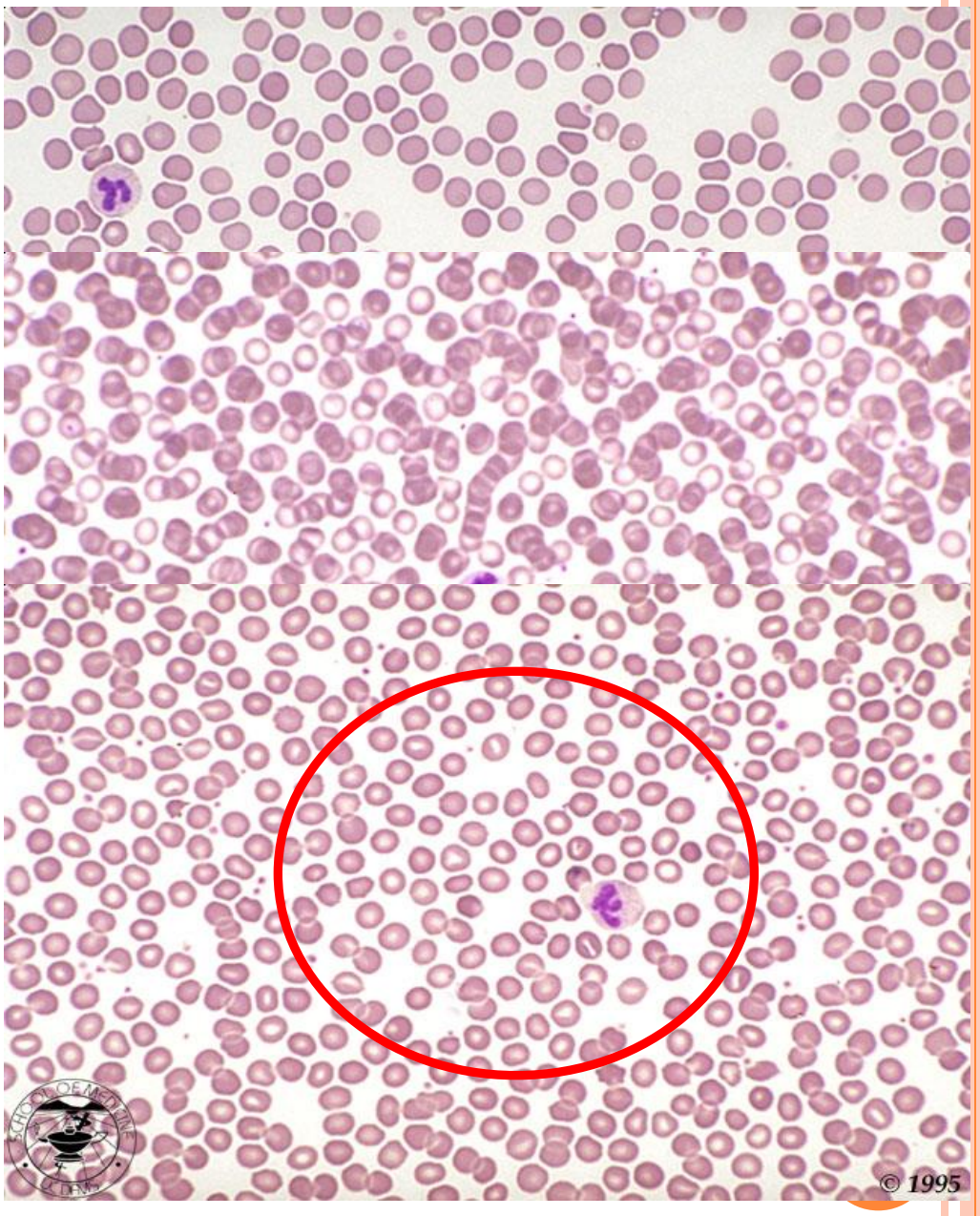
© 1995

DEMIR EKSIKLIĞI ANEMISI

	Sample ID	Cass / Pos	Date	Time	Asp Mode	Status	Instrume
CBC(+Diff,+Retic)	03189	002909	9/25/2002	11:33:50	Auto	Completed	Instrumen
Retic Only							

Parameters | Demographics | CBC Data | Diff Data | Retic Data

WBC	7.9			RBC	4.42	RET %	
				HGB	10.5 L	RET #	
NE %	70.7	NE #	5.6	HCT	32.6 L	MRV	
LY %	22.8	LY #	1.8	MCV	73.8 L	IRF	
MO %	5.2	MO #	0.4	MCH	23.8 aL	@ MSCV	
EO %	0.6 L	EO #	0.0	MCHC	32.3 L	@ HLR %	
BA %	0.7	BA #	0.1	RDW	18.6 H	@ HLR #	
				PLT	520 H	@ PCT	0.378
				MPV	7.3	@ PDW	18.0

Beta Talasemi Minör (Trait)

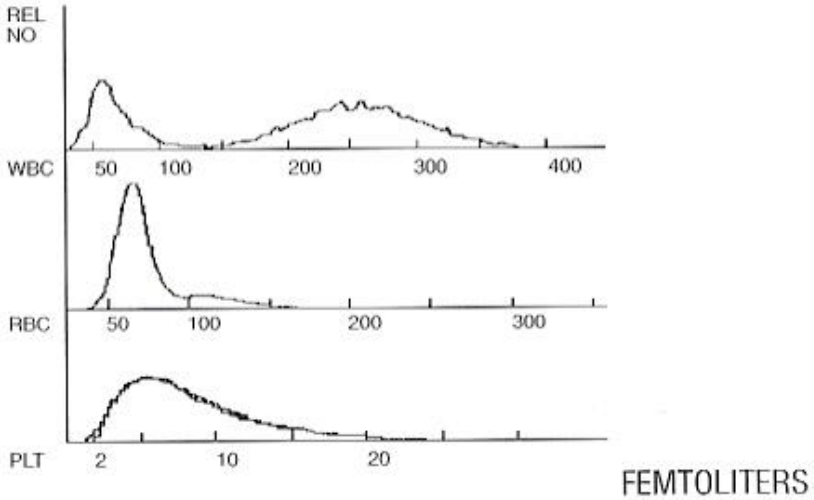

WBC	8.8	
LY%	28.6	
MO%	1.1	L
GR%	70.3	
LY#	2.5	
MO#	0.1	
GR#	6.2	
RBC	3.85	L
Hgb	7.7	L
Hct	25.4	L
MCV	66.0	L
MCH	20.0	L
MCHC	30.3	L
RDW	14.9	
PLT	314	
MPV	11.9	H

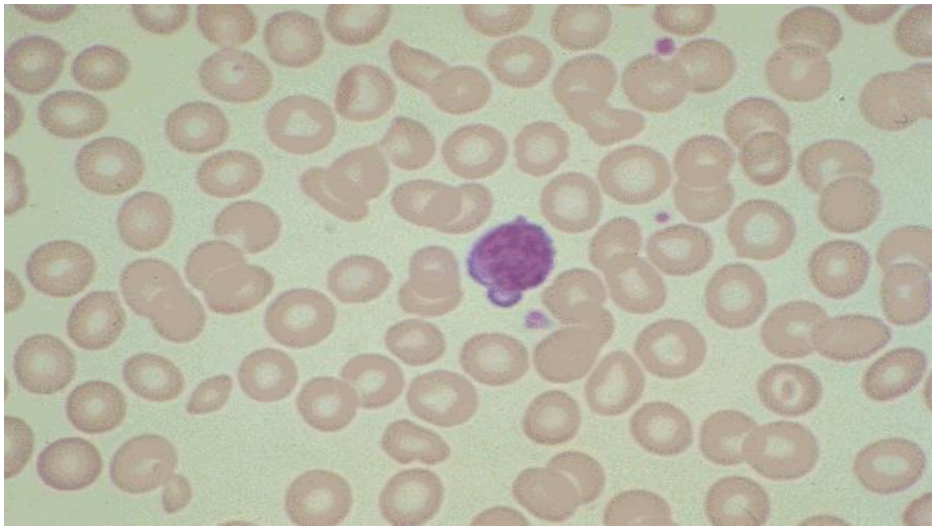

Ülkemizde Anemi Nedenleri

- Normositer Anemiler
  - Akut kanamalar
  - Hemolitik anemiler (Orak HA)
  - Kronik Hastalık Anemisi
- Mikrositer Anemiler
  - DEA
  - Talassemiler
- Makrositer Anemiler
  - Megaloblastik Anemiler (Vit B12 ve FA eks.)

Normositik anemi

Eritrosit üretiminde artış?

Retikülosit sayımını kontrol et

artmış

hemoliz?

evet

hayır

Hemolitik anemi

Kanama

Normal veya azalmış

- Böbrek yetmezliği
- Endokrin hastalık
- Kronik inflamasyon

Yoksa primer Kİ problemi (MDS, MM, infiltrasyon…)

KİAB

Normal OEH ve Düşük Retikülosit

Ayırıcı Tanı

- **Primer Kİ Yetm**
  - Aplastik anemi
  - Akkiz KK aplazisi
  - Miyelofitizis
- **Sekonder Kİ Yetm**
  - Üremi
  - Endokrinoloji
    - hipotiroidizm
    - hipogonadizm
    - pan-hipopituitarizm
  - HIV
  - Kronik Hastalık Anemisi

Makrositer anemi

- **Megaloblastik anemi**
  - Vitamin B12 eksikliği
  - Folat eksikliği
  - MDS
  - İlaca bağlı
- **Nonmegaloblastik anemi**
  - Karaciğer hastalığı
  - Hipotiroidizm
  - Alkol

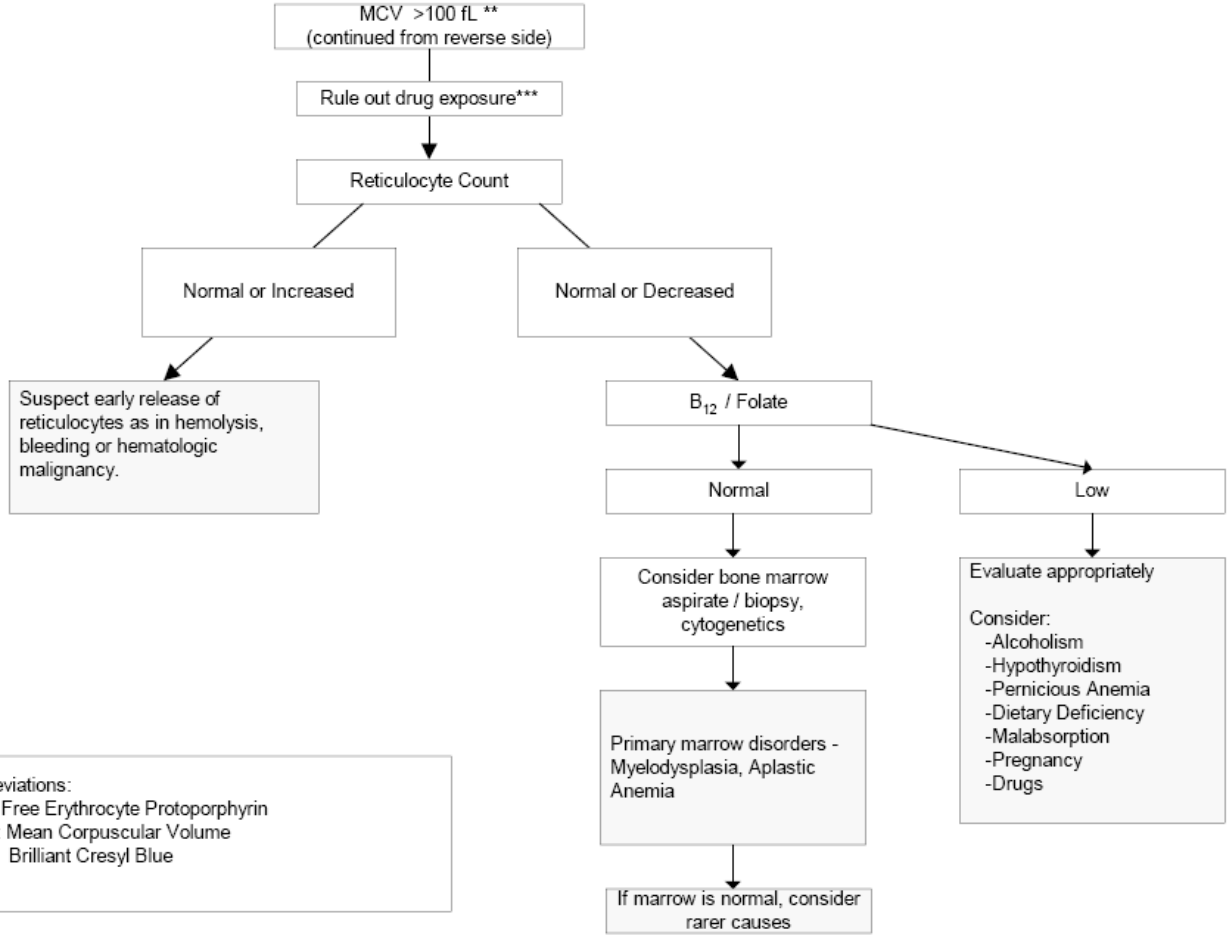

Abbreviations:
FEP: Free Erythrocyte Protoporphyrin
MCV: Mean Corpuscular Volume
BCB: Brilliant Cresyl Blue

**Artifactual macrocytosis , determined by automated counters, may be caused by cold agglutinins, hyperglycemia, marked leukocytosis, RBC clumping, intracellular hypersensitivity.

***Some drugs that may cause macrocytosis: alcohol, chemotherapy drugs, zidovudine, anti-convulsants, oral contraceptives, triamterene, sulfasalazine, sulfamethoxazole, trimethoprim, colchicine, PASA, neomycin, nitrous oxide

References:
1. Beuerlein, Frank. Testing Strategies for Anemias. Laboratory Mangement. December 1988.
2. Lee, G. Richard, Bithell, Thomas C., Foerster, John, Athens, John, Lukens, John. Wintrobe's Clinical Hematology, Edition 10, 1999.

Originally published: October 1999
Reviewed: October 2001; October 2004 (changes made)

- Yanlış düşük serum kobalamin düzeyi

Folat eksikliği

Multipl myeloma

Transkobalamin 1 eksikliği

Megadoz vitamin C tedavisi

- Yanlış yüksek serum kobalamin düzeyi

Transkobalamin I-II arttığı durumlar(myeloproliferatif hast,hepatoma)

Transkobalamin II üreten makrofajların artışı(otoimmün hast, monoblastik lösemi, lenfoma)

Hepatositlerden kobalamin salınımı (Aktif KC hast)

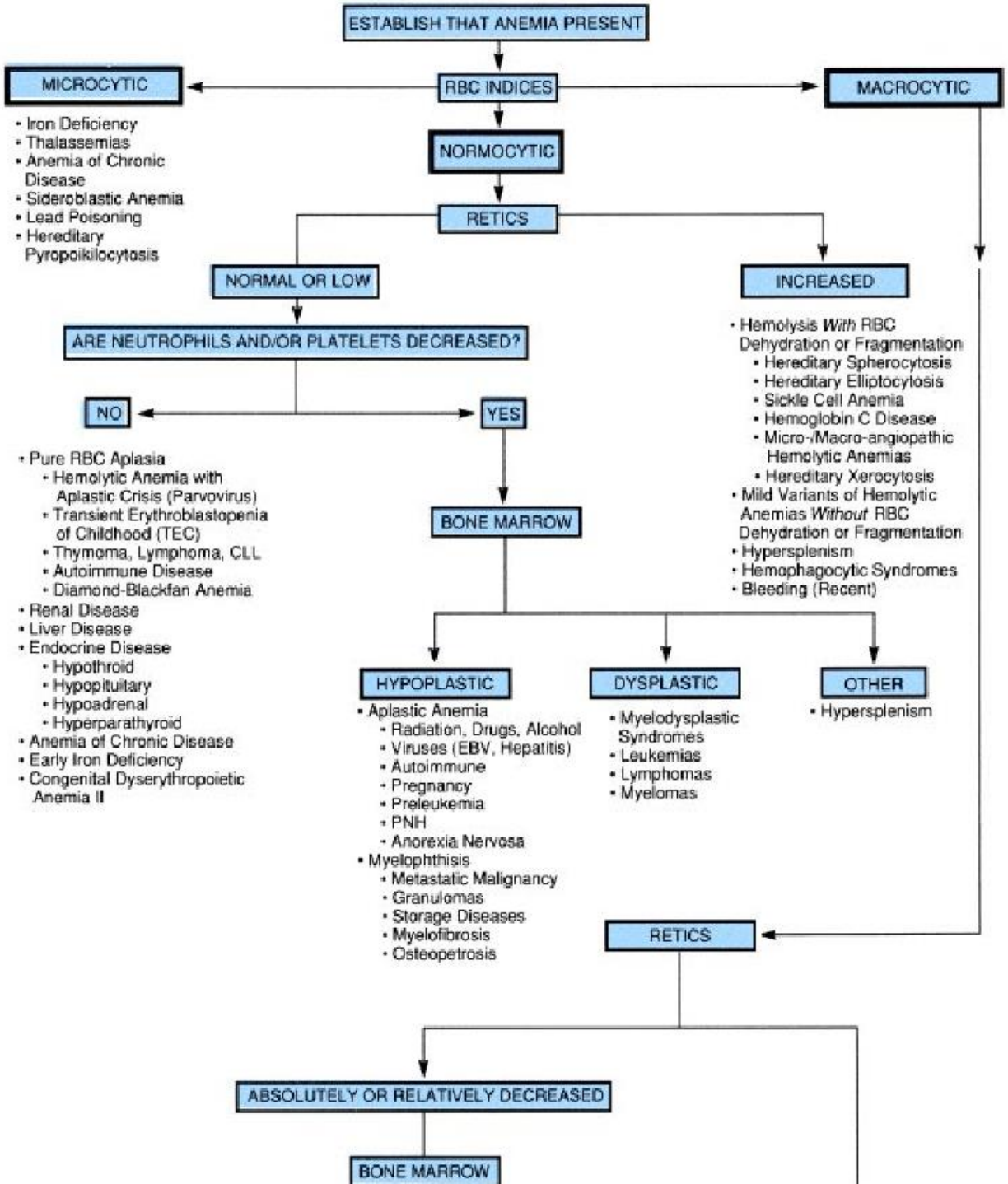
ESTABLISH THAT ANEMIA PRESENT
RBC INDICES
MICROCYTIC
MACROCYTIC
• Iron Deficiency
• Thalassemias
• Anemia of Chronic Disease
• Sideroblastic Anemia
• Lead Poisoning
• Hereditary Pyropoikilocytosis
NORMOCYTIC
RETICS
NORMAL OR LOW
INCREASED
• Hemolysis With RBC Dehydration or Fragmentation
• Hereditary Spherocytosis
• Hereditary Elliptocytosis
• Sickle Cell Anemia
• Hemoglobin C Disease
• Micro-/Macro-angiopathic Hemolytic Anemias
• Hereditary Xerocytosis
• Mild Variants of Hemolytic Anemias Without RBC Dehydration or Fragmentation
• Hypersplenism
• Hemophagocytic Syndromes
• Bleeding (Recent)
ARE NEUTROPHILS AND/OR PLATELETS DECREASED?
NO
YES
• Pure RBC Aplasia
• Hemolytic Anemia with Aplastic Crisis (Parvovirus)
• Transient Erythroblastopenia of Childhood (TEC)
• Thymoma, Lymphoma, CLL
• Autoimmune Disease
• Diamond-Blackfan Anemia
• Renal Disease
• Liver Disease
• Endocrine Disease
• Hypothroid
• Hypopituitary
• Hypoadrenal
• Hyperparathyroid
• Anemia of Chronic Disease
• Early Iron Deficiency
• Congenital Dyserythropoietic Anemia II
BONE MARROW
HYPOPLASTIC
• Aplastic Anemia
• Radiation, Drugs, Alcohol
• Viruses (EBV, Hepatitis)
• Autoimmune
• Pregnancy
• Preleukemia
• PNH
• Anorexia Nervosa
• Myelophthisis
• Metastatic Malignancy
• Granulomas
• Storage Diseases
• Myelofibrosis
• Osteopetrosis
DYSPLASTIC
• Myelodysplastic Syndromes
• Leukemias
• Lymphomas
• Myelomas
OTHER
• Hypersplenism
RETICS
ABSOLUTELY OR RELATIVELY DECREASED
BONE MARROW

Laboratory Evaluation of Anemia in Adults

Washington State Clinical Laboratory Advisory Council

FOR EDUCATIONAL PURPOSES ONLY

The individual clinician is in the best position to determine which tests are most appropriate for a particular patient.

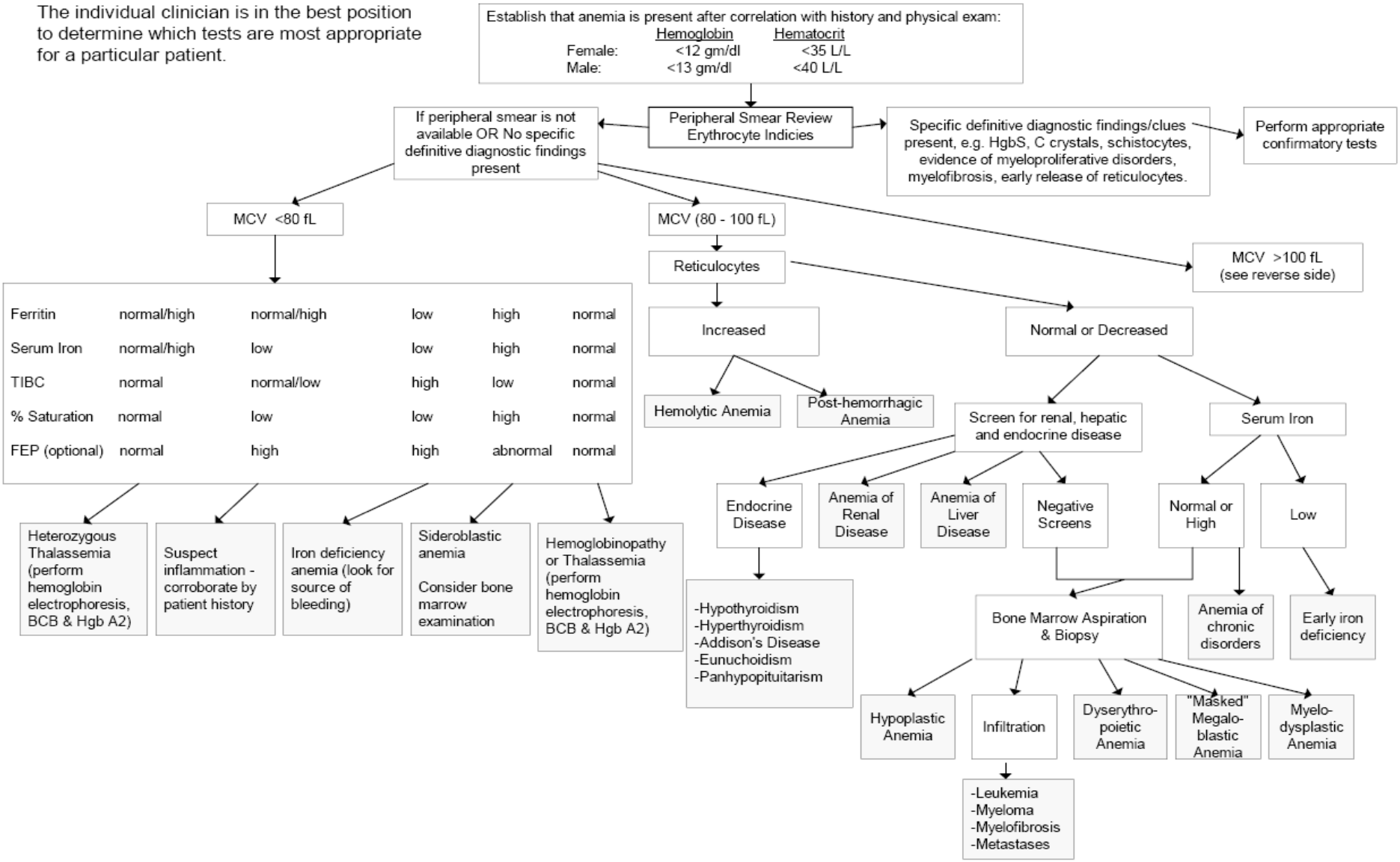

ANEMİ ALGORİTMASI

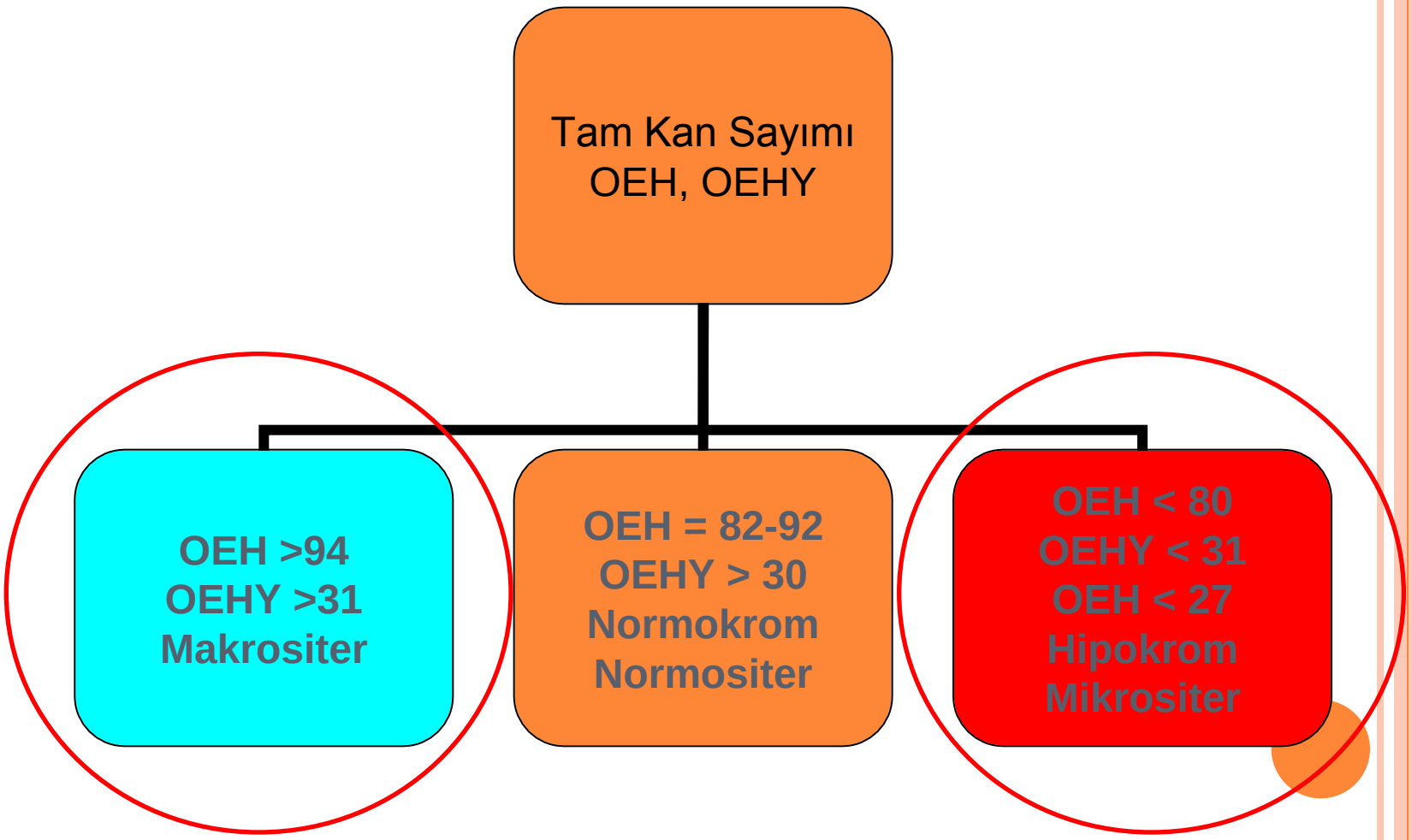

Makrositer Anemi

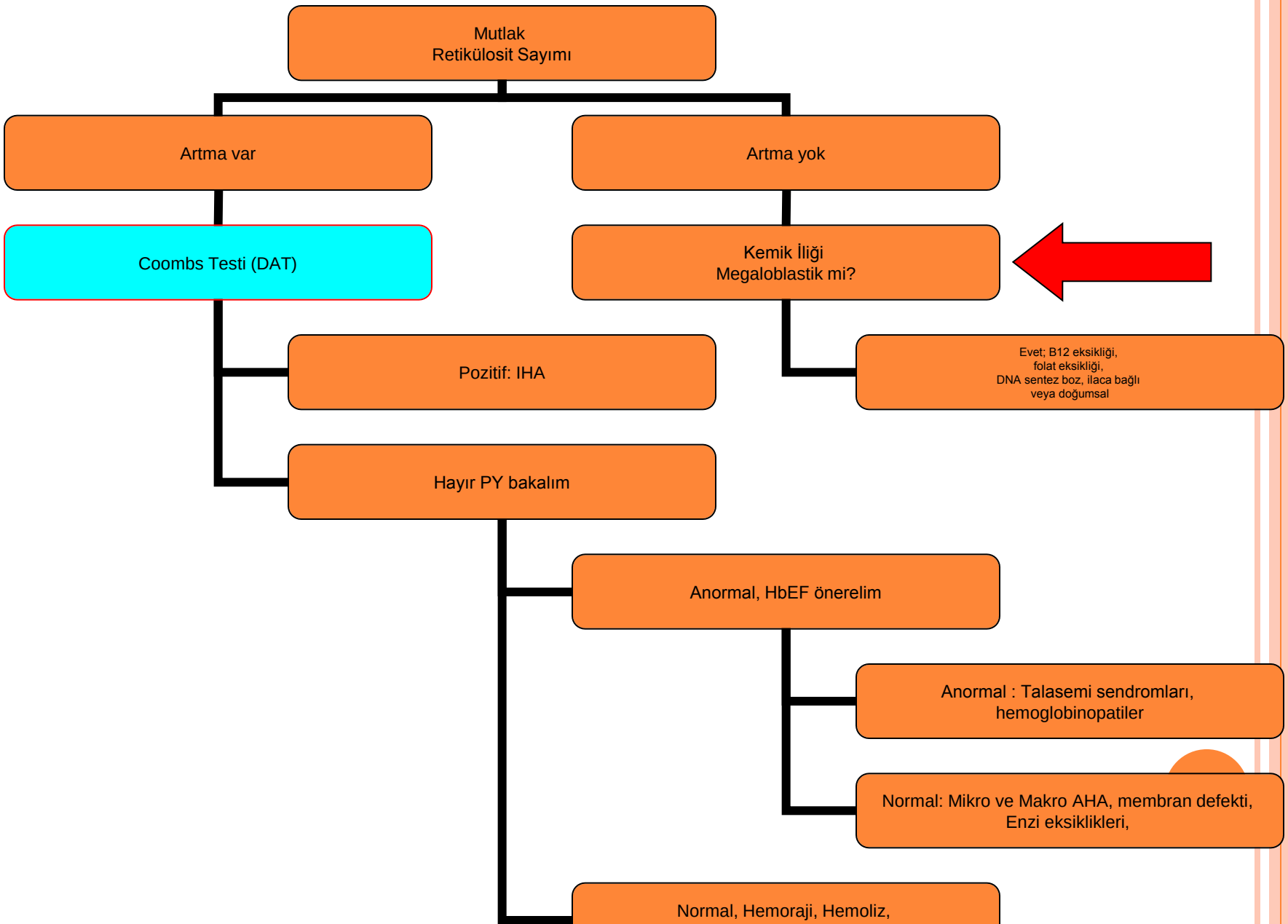

NORMOSITER ANEMILER

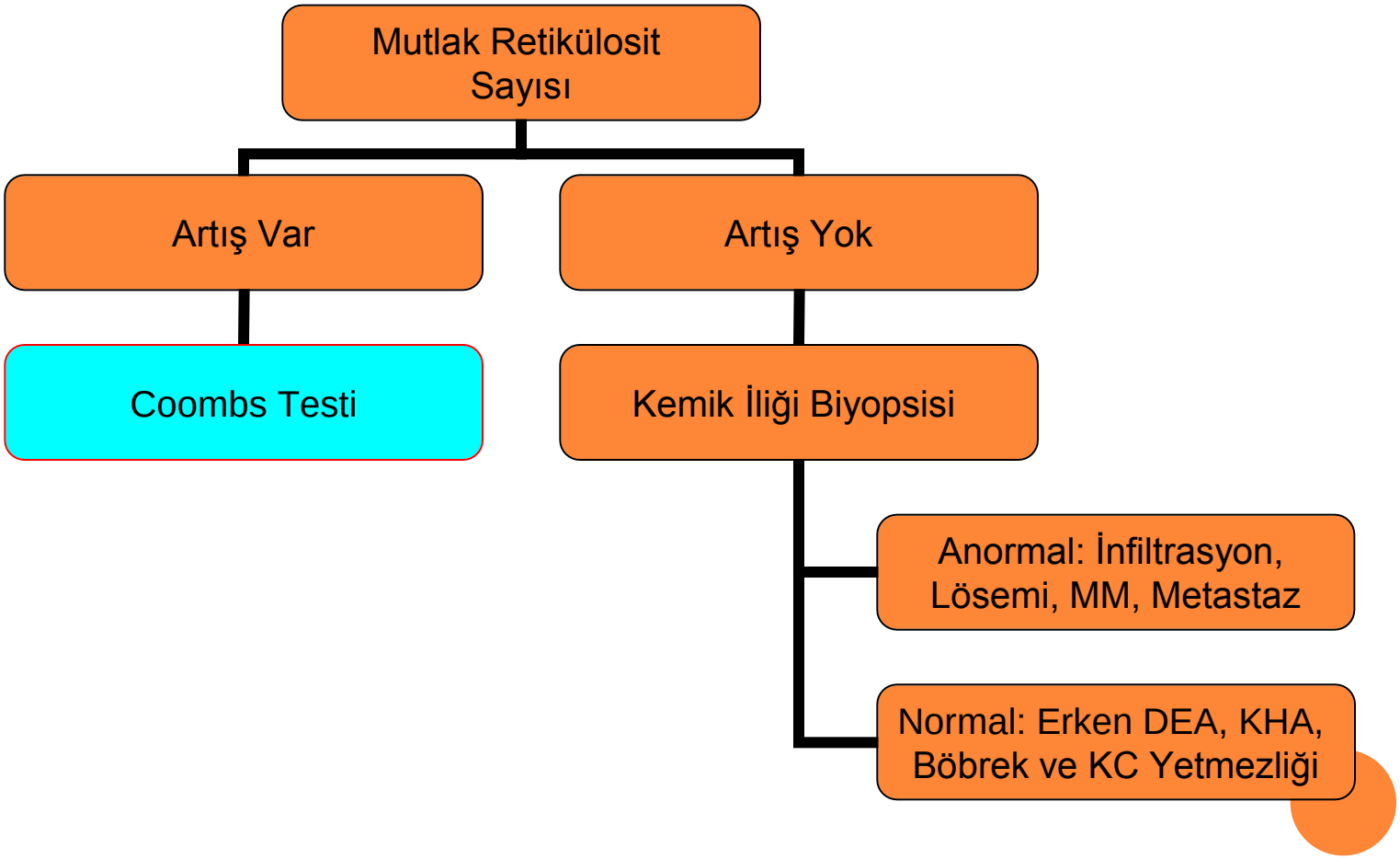

Mikrositer Anemiler

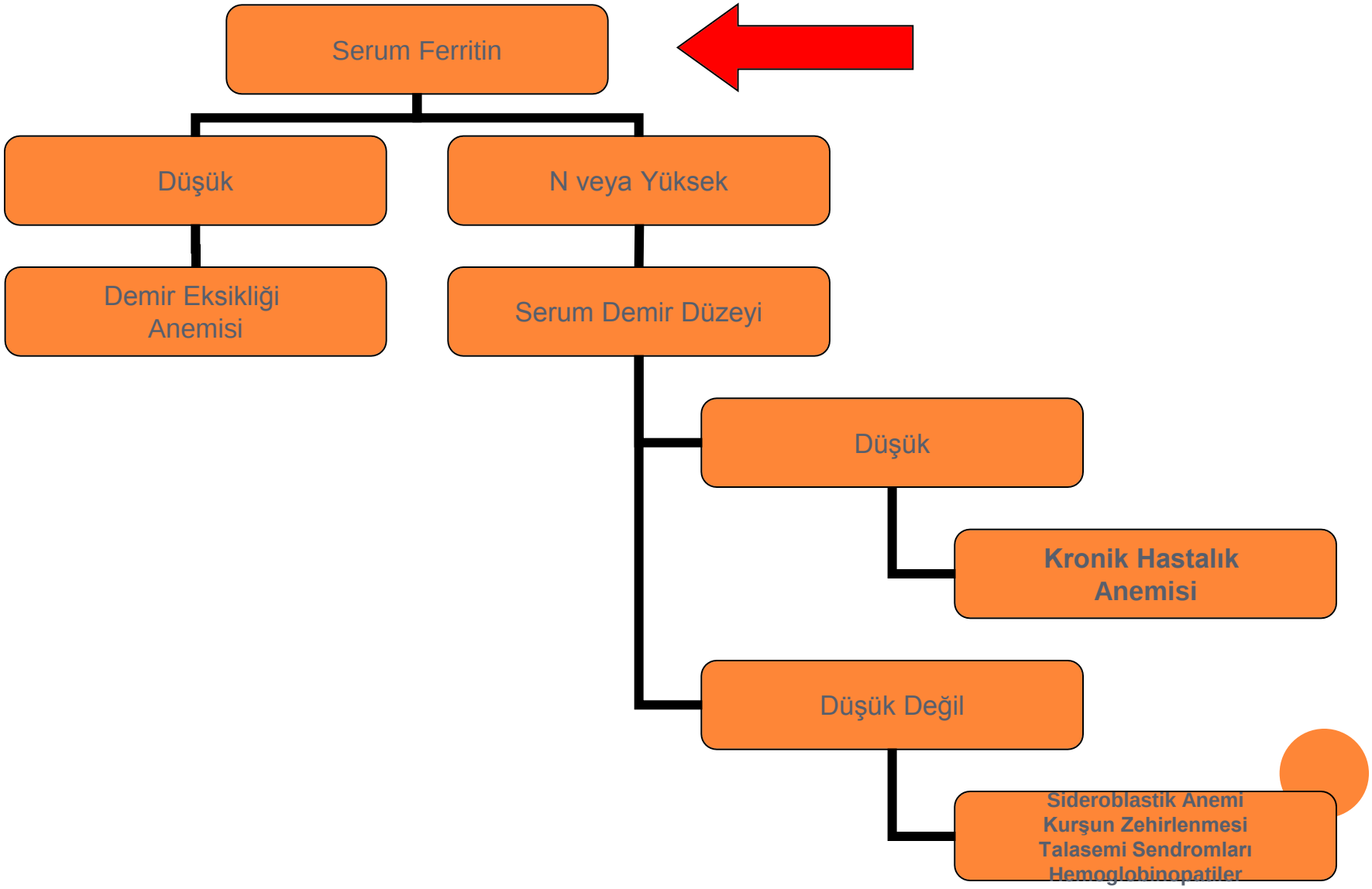

Pernicious Anemia - 2.
Note the hypersegmented neutrophil (7-8 lobes).

Normochromic normocytic anemia

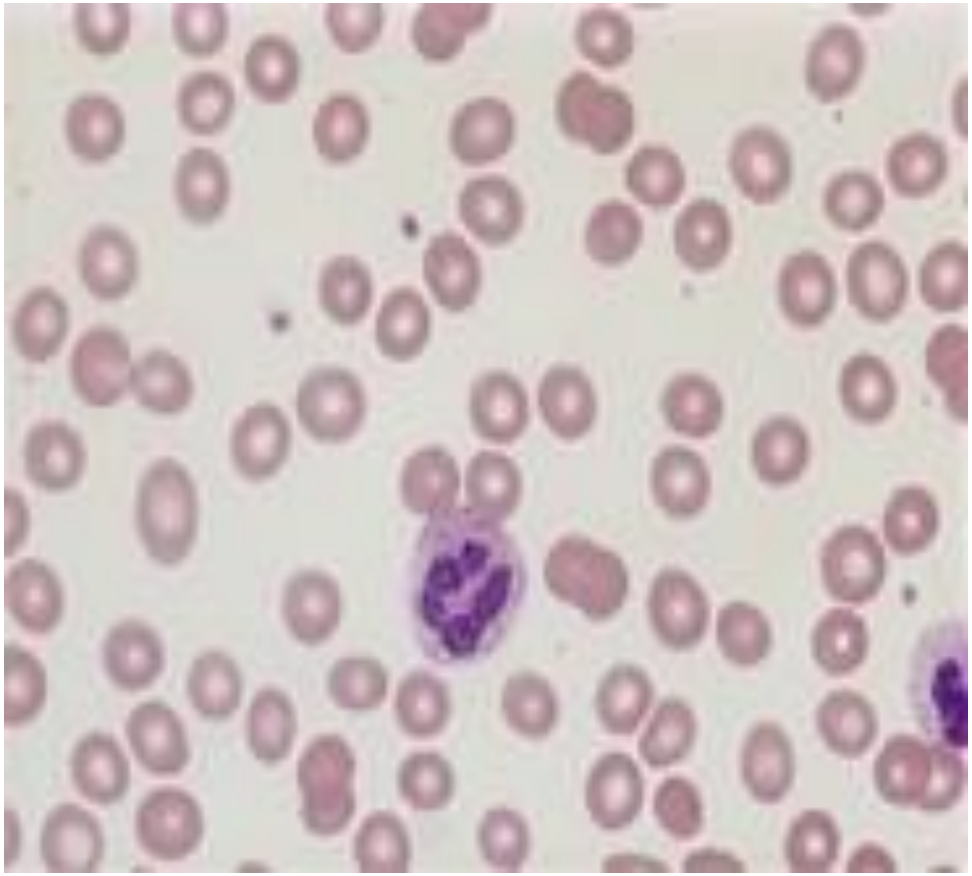

Microangiopathic hemolytic anemia

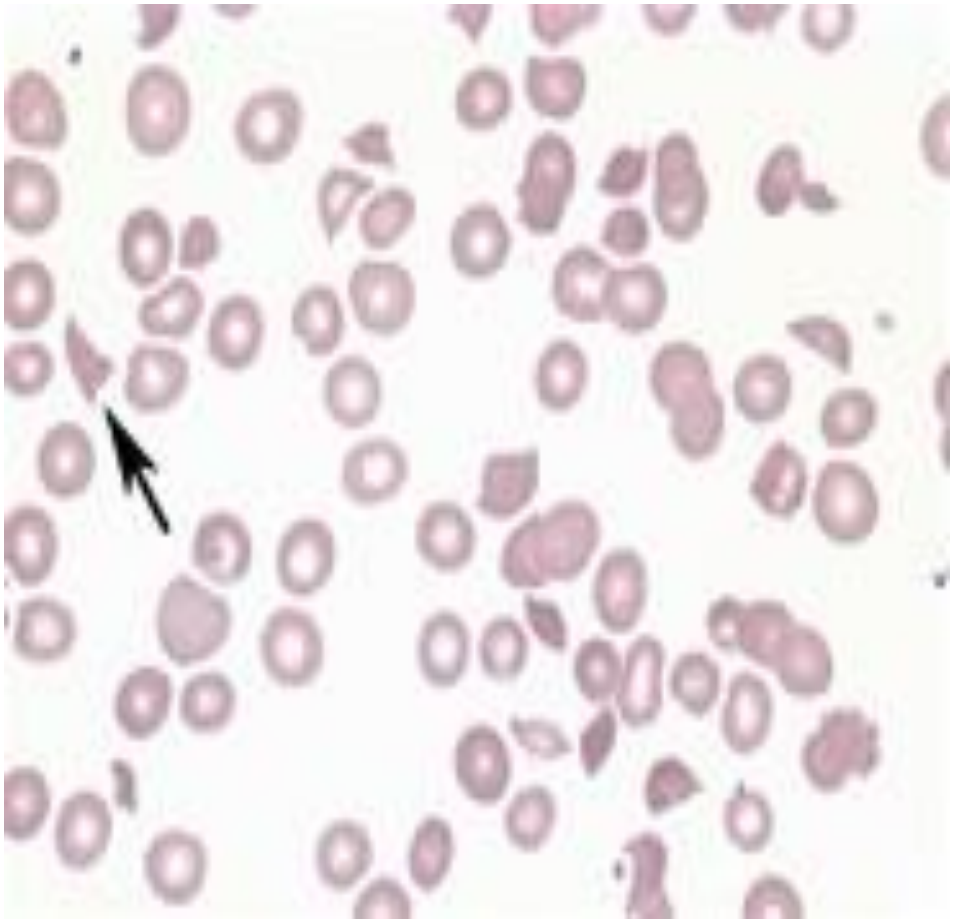

Spur Cell Anemia

Peripheral smear on a 49 year old male with history of alcoholic cirrhois who had a sudden drop in hemoglobin associated with worsening jaundice. RBCs with spike like projections (spur cells), target cells and RBC fragments are prominent.

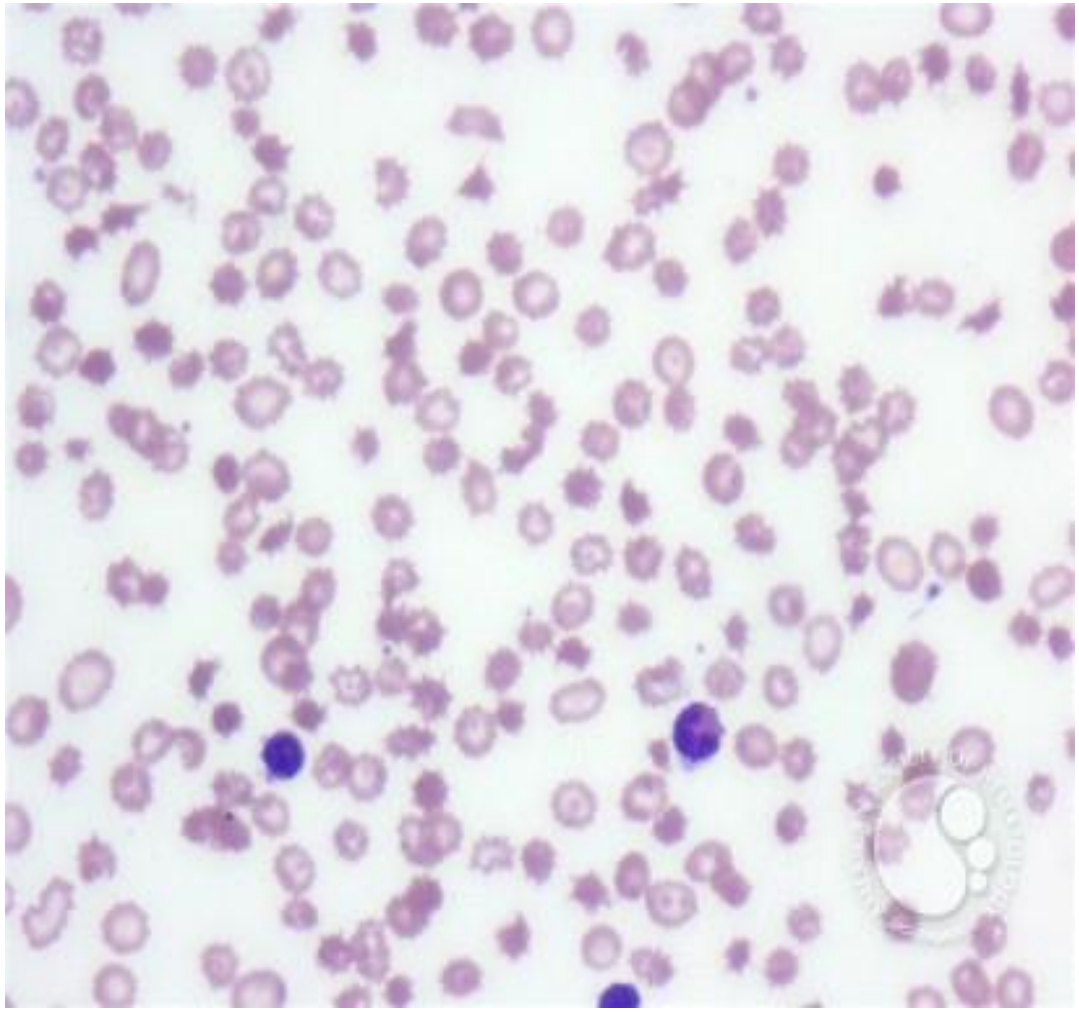

Most cases of TTP show congenital or acquired deficiencies or dysfunction of the ADAMTS 13 protease. With the patient noted above, the measurement of this protease was unavailable.

blood

Neil Abramson, Baptist Cancer Institute A 57-year-old woman with breast cancer refractory to several combinations of chemotherapy was placed on a regimen that included mitomycin.

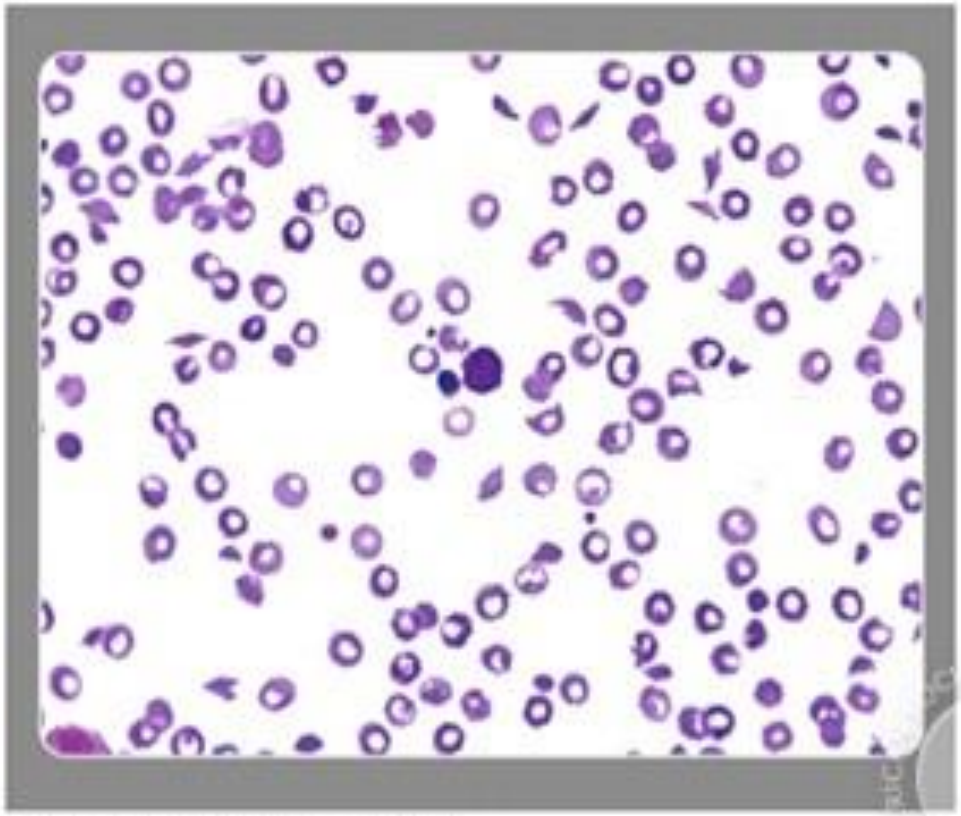

American Society of Hematology et al. Blood 2007;110:2229-2229

©2007 by American Society of Hematology

Cold agglutinin disease with PLL

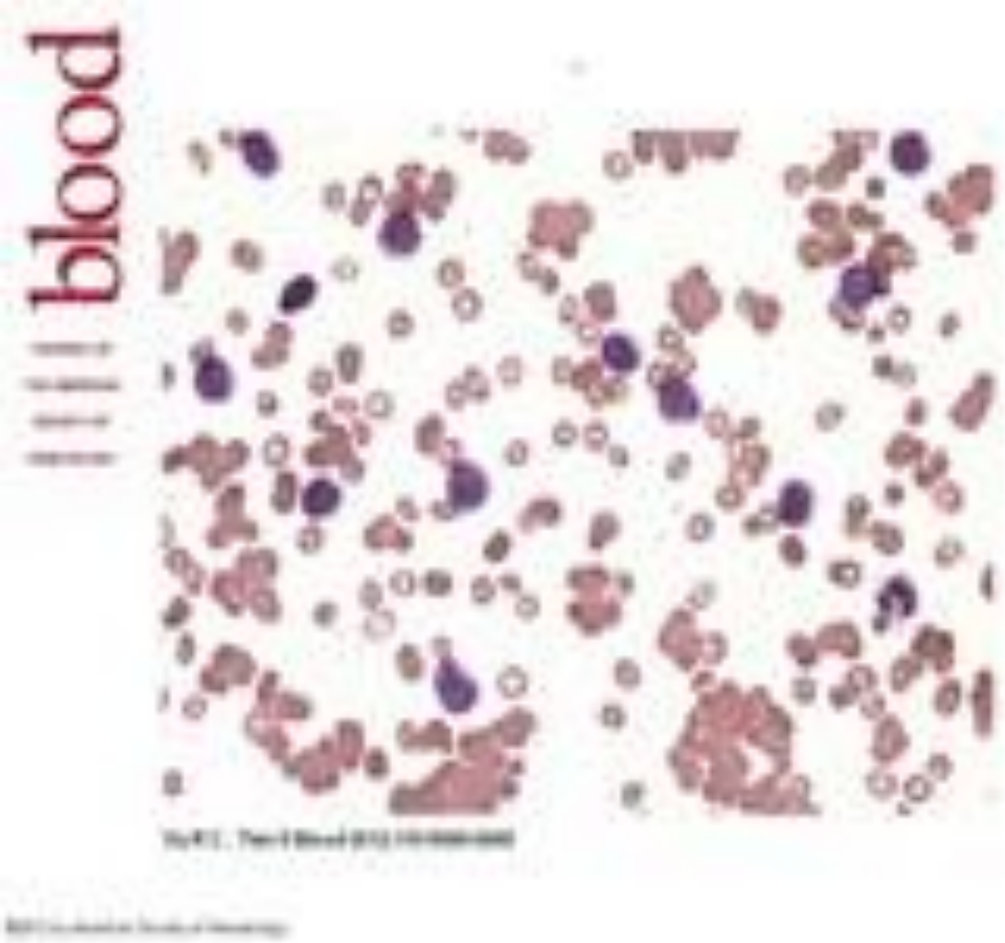

Doublet spherocytes

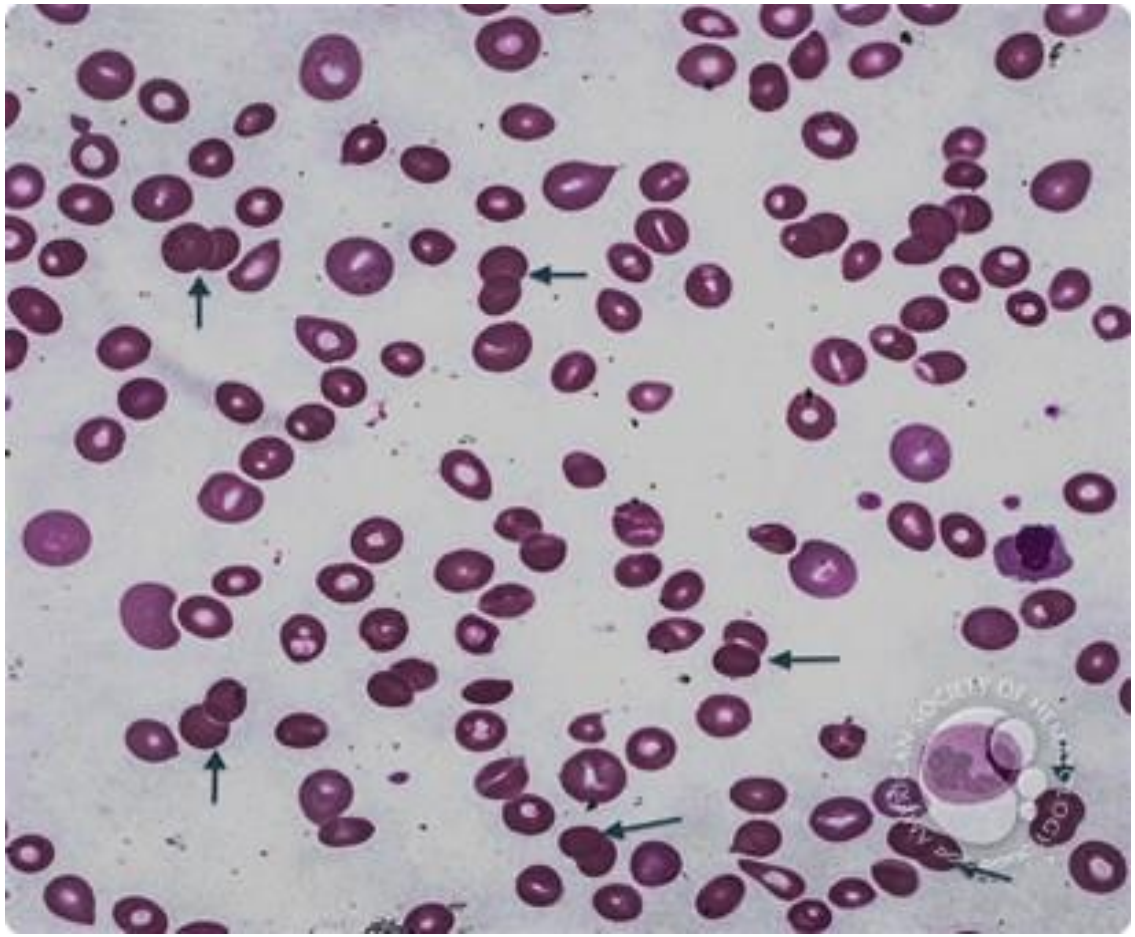

Hereditary pyropoikilocytosis

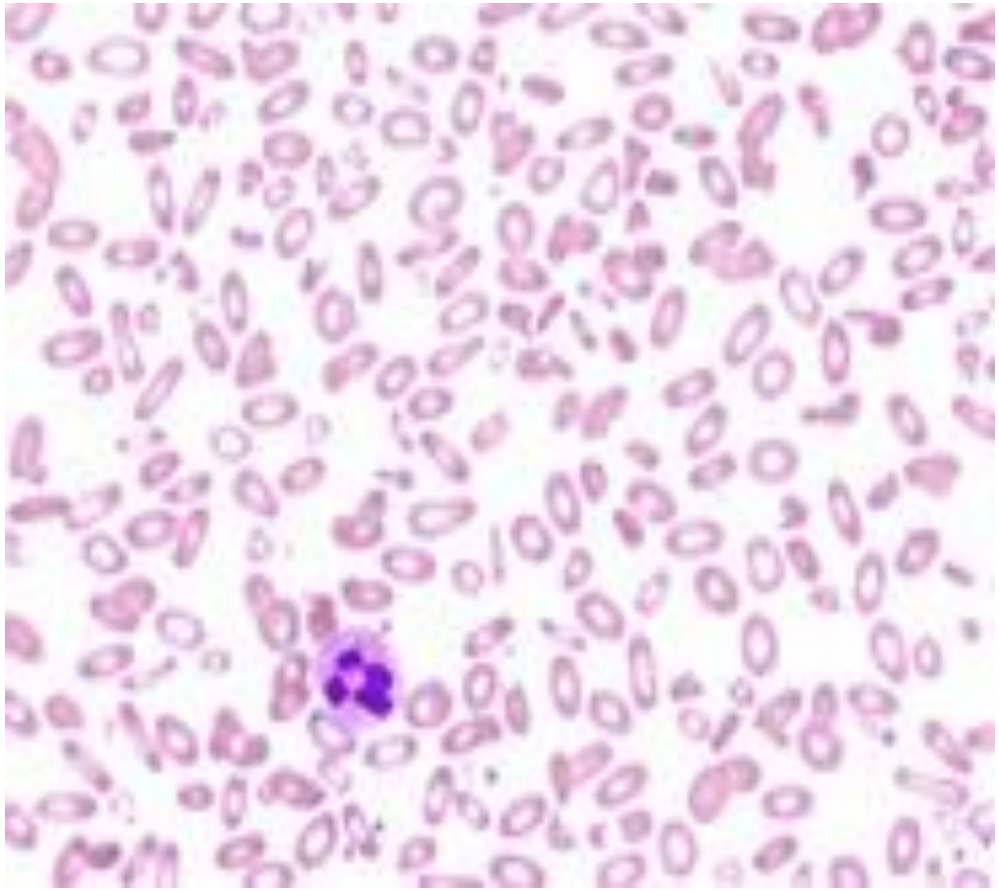

Howell-Jolly bodies are red cell inclusions which are residual nuclear fragments. They may be seen in hemolysis, megaloblastic anemia, or post-splenectomy.

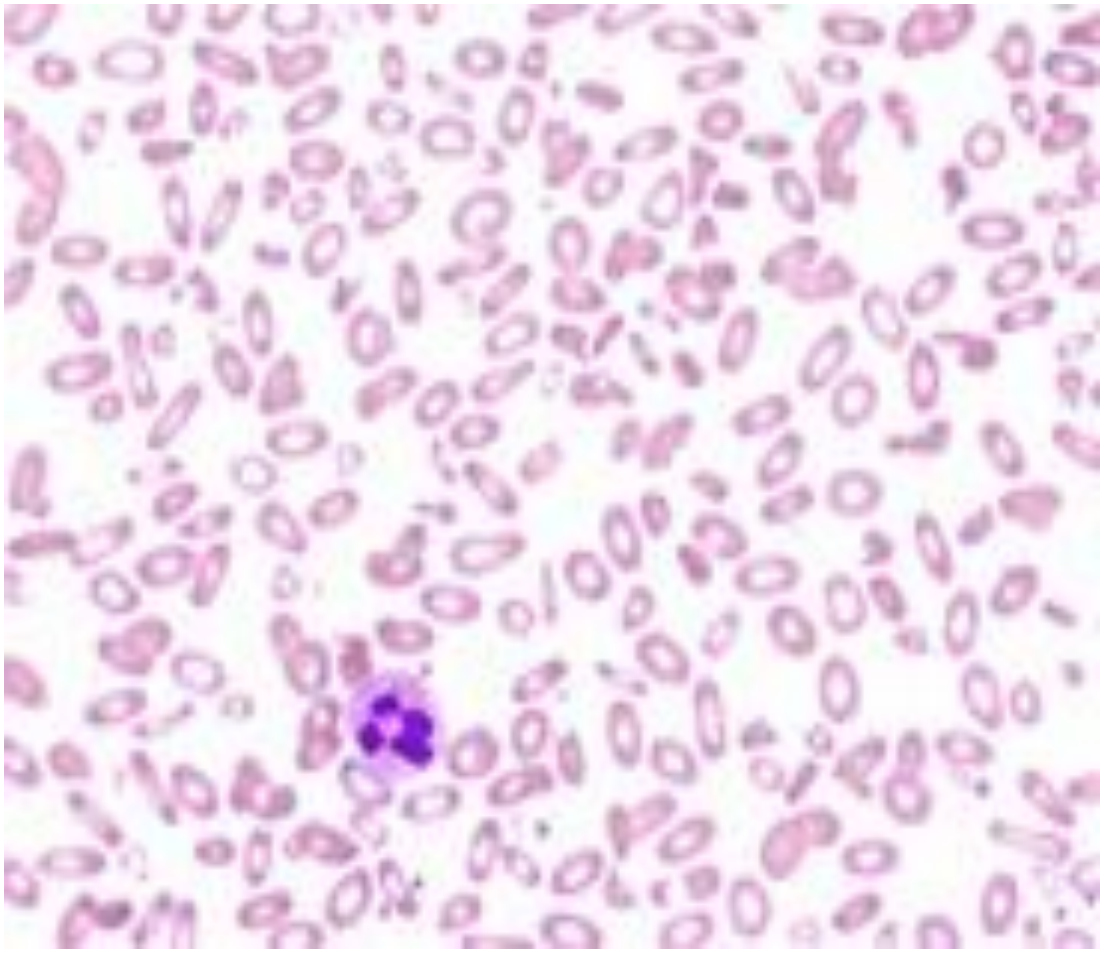

Basophilic Stippling - Lead Poisoning - 3.

Although the coarse stippling is most prominent in the polychromatophilic cells, the mature RBCs noted in the center of the slide also have similar single inclusions.

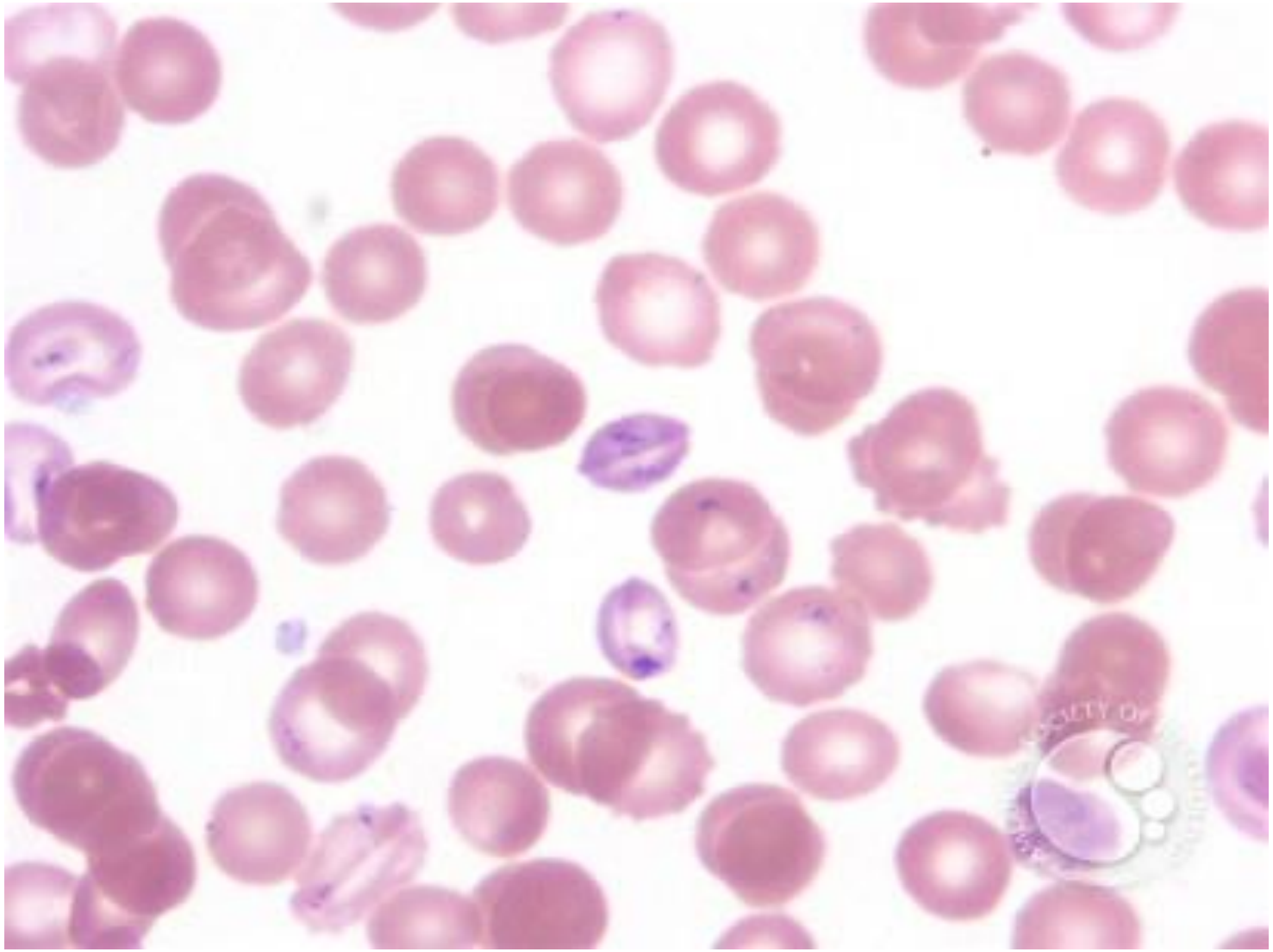

Malaria - 2.

Double-dot patterns may be seen in the trophozoite stage of P. falciparum. Subtle stippling may be seen in some of the surrounding erythrocytes.

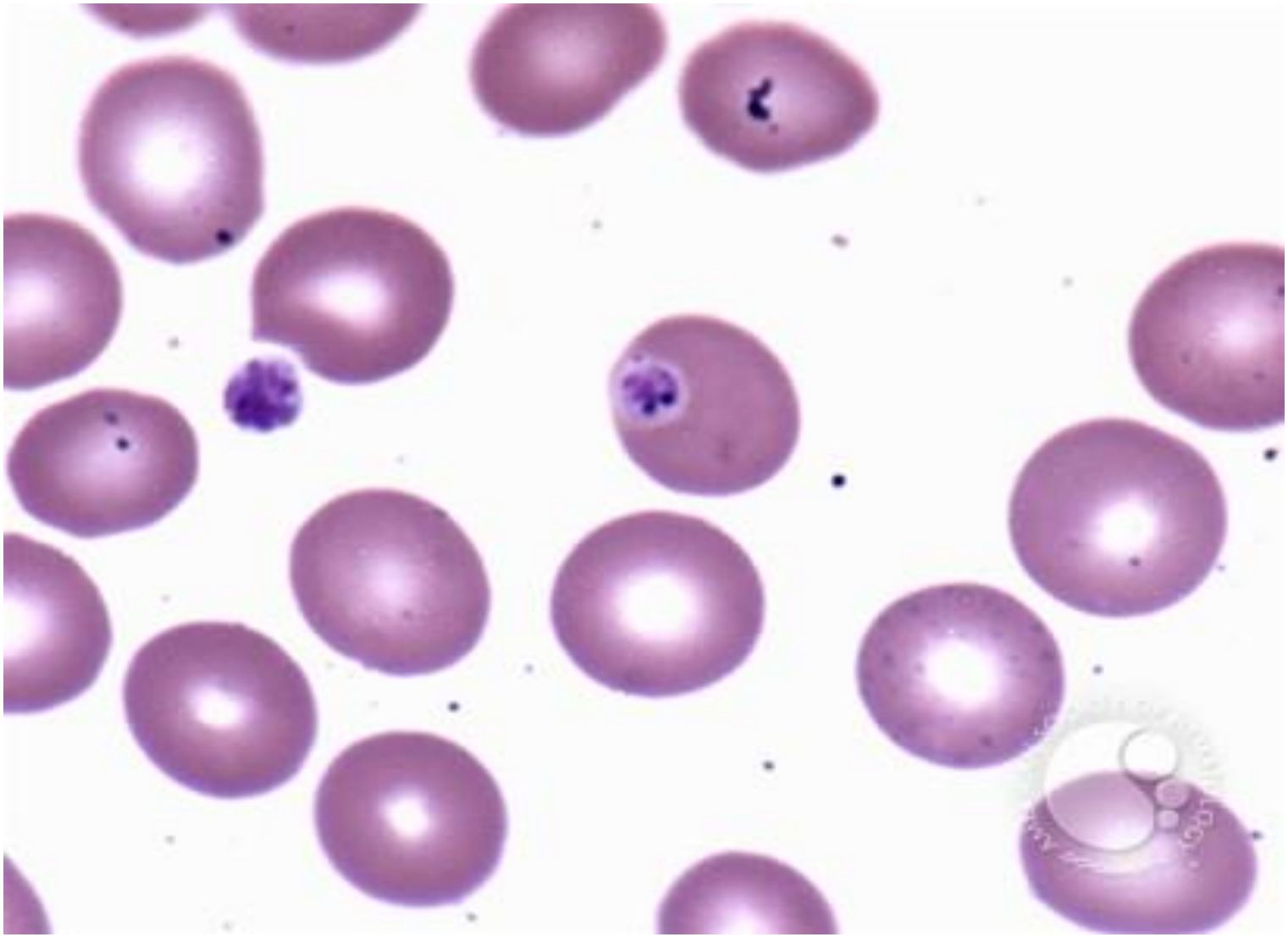

RBC agglutination - 3.

When the blood sample is warmed to 37°C for several minutes and a peripheral smear prepared on a pre-warmed slide, the agglutination is markedly decreased with single RBCs now predominant.

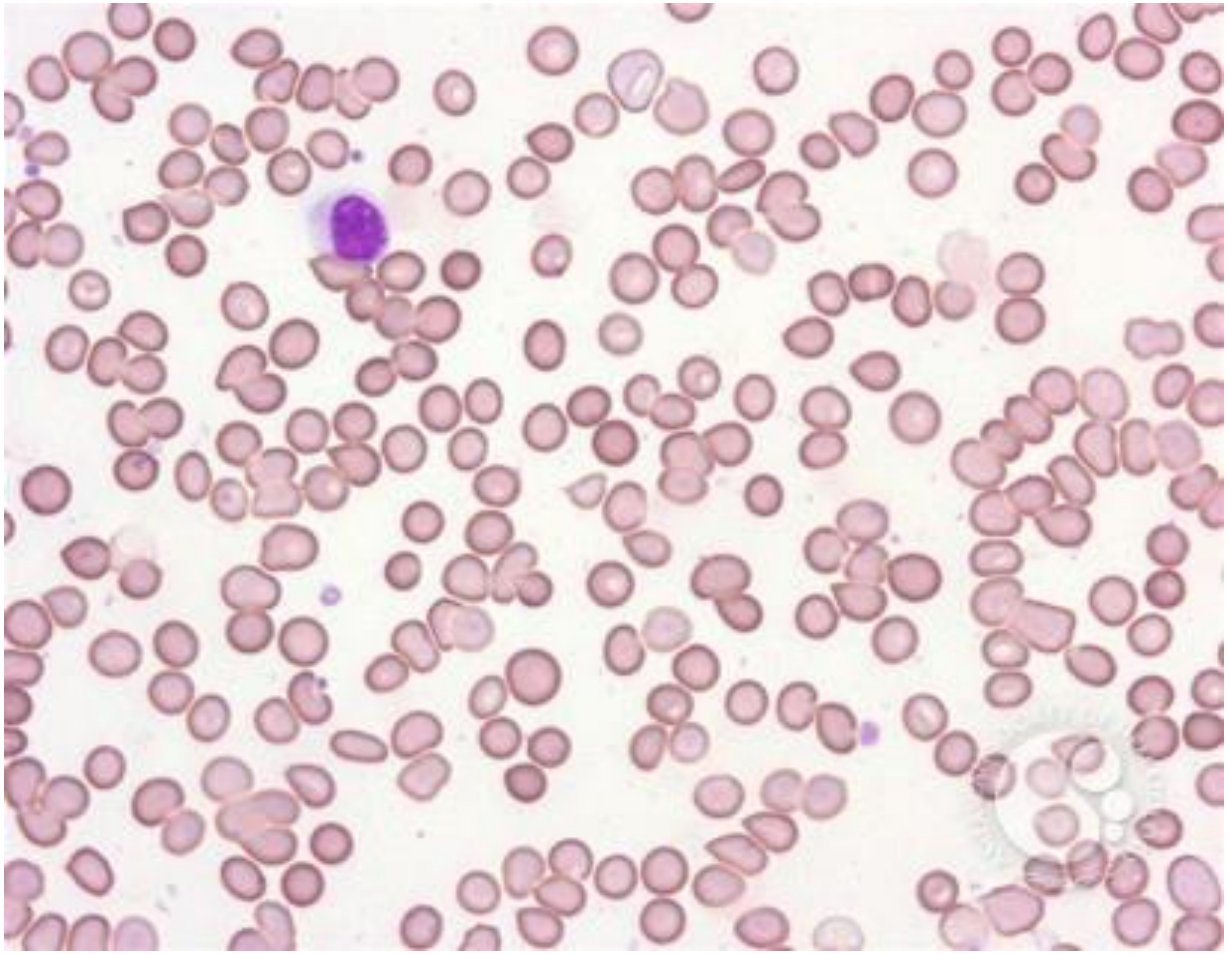

Neuroblastoma - 2.

In a different area of the aspirate, cells characteristically "stick together" giving a clue to their extrinsic origin.

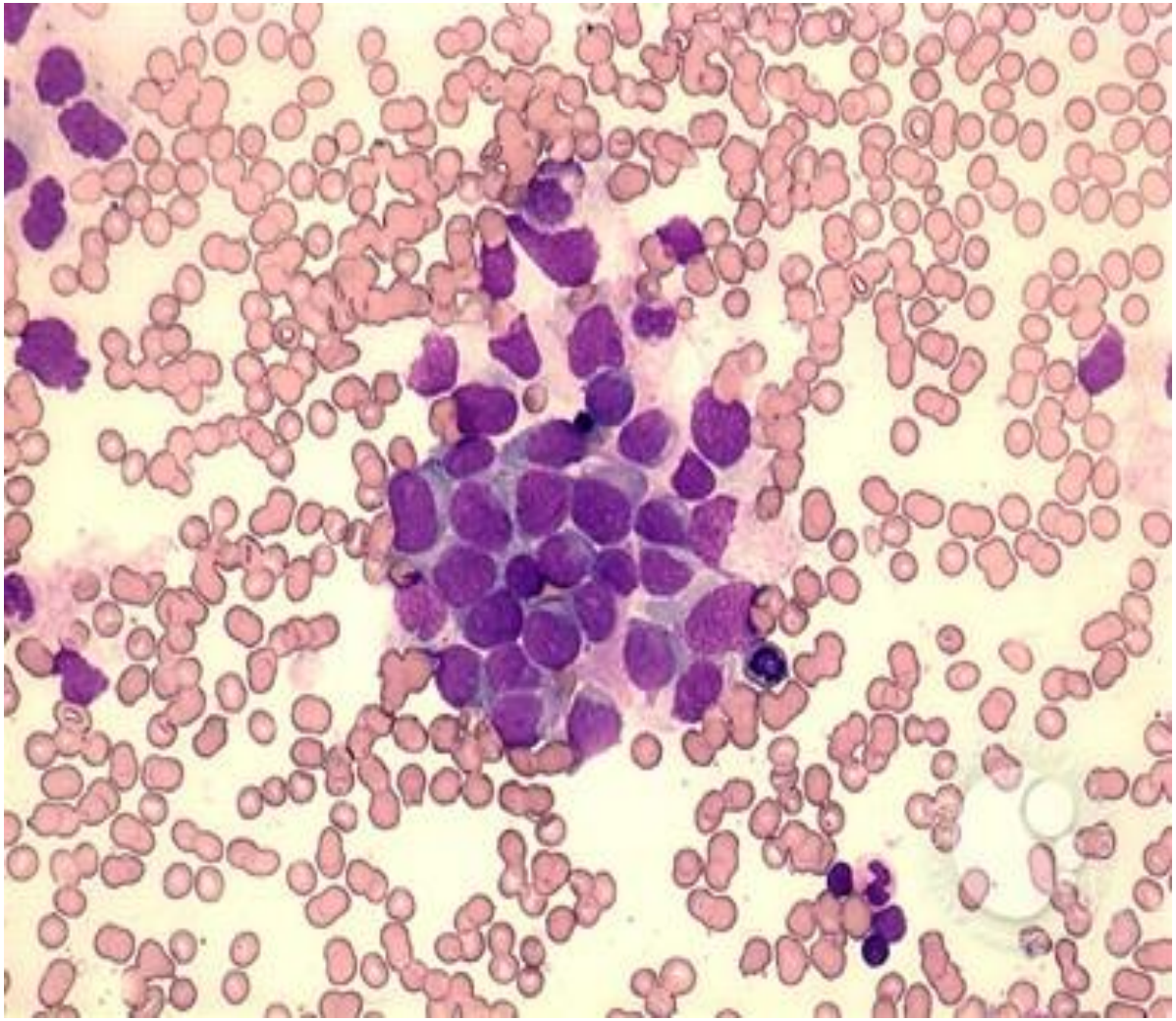

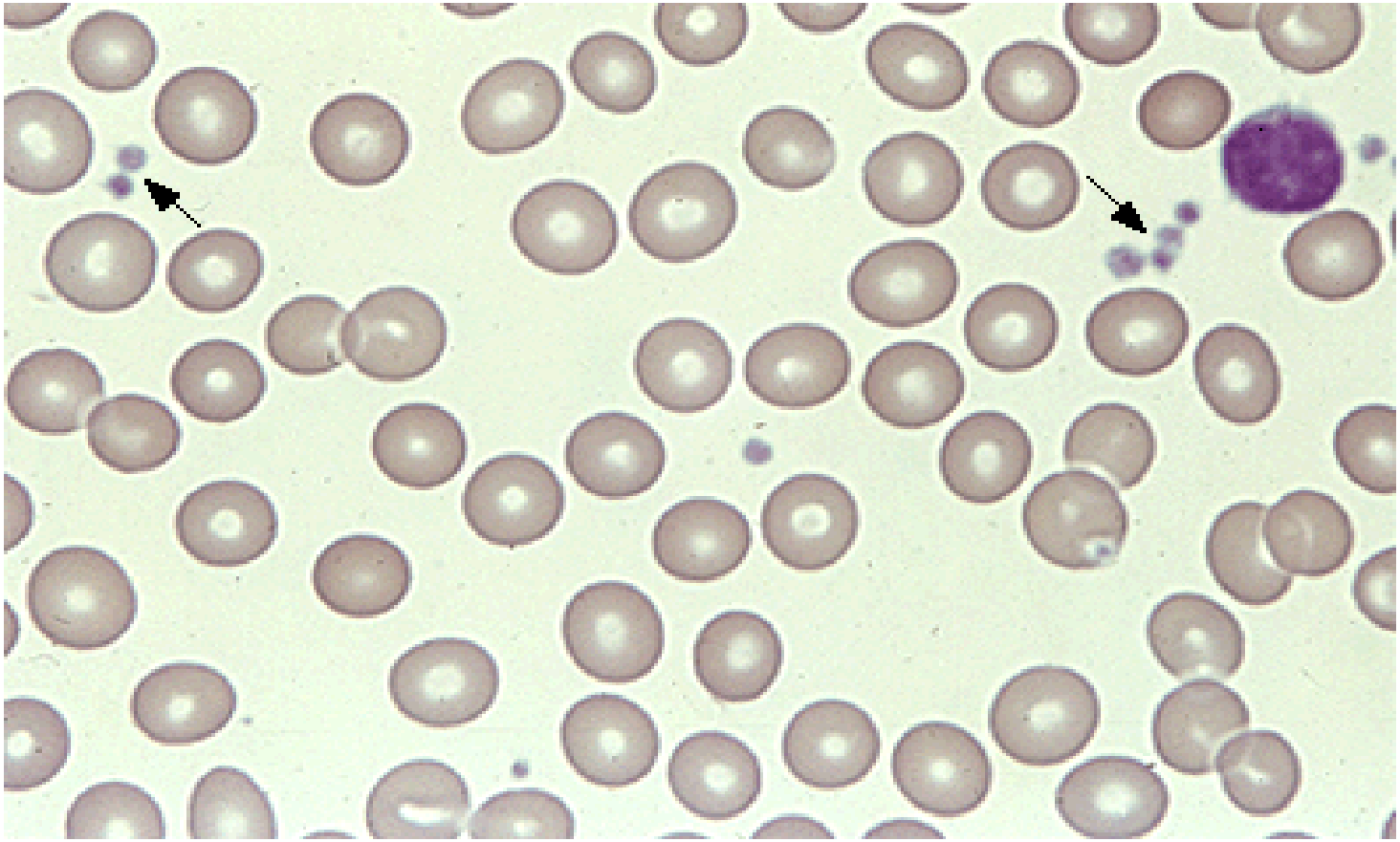

Normal peripheral blood smear High power view of a normal peripheral blood smear. Several platelets (arrows) and a normal lymphocyte can also be seen. The red cells are of relatively uniform size and shape. The diameter of the normal red cell should approximate that of the nucleus of the small lymphocyte; central pallor should equal one-third of its diameter. Courtesy of Carola von Kapff, SH (ASCP).

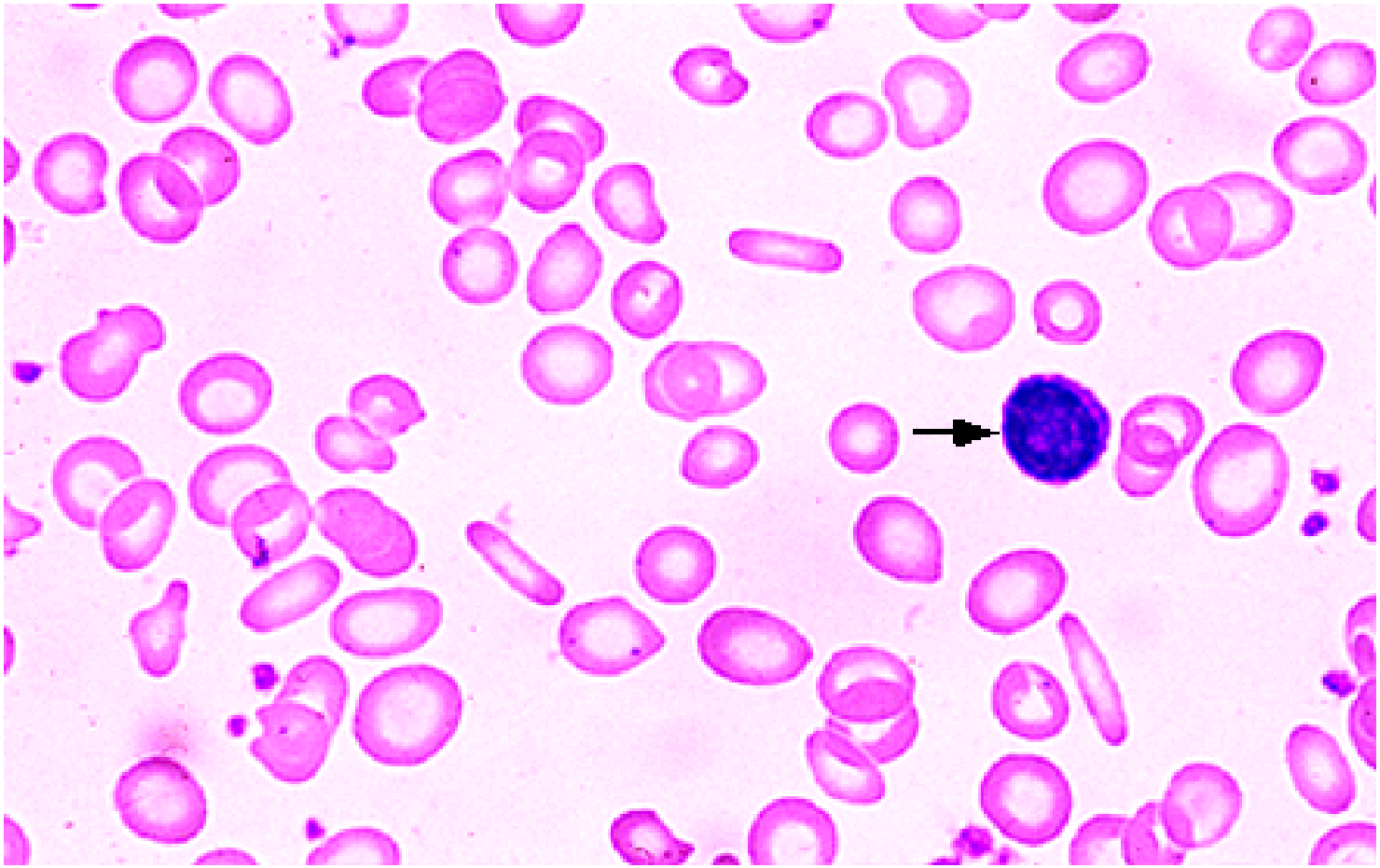

Microcytic hypochromic red cells Peripheral smear from a patient with iron deficiency shows pale small red cells with just a scant rim of pink hemoglobin; occasional "pencil" shaped cells are also present. Normal red cells are similar in size to the nucleus of a small lymphocyte (arrow); thus, many microcytic cells are present in this smear. Thalassemia can produce similar findings. Courtesy of Carola von Kapff, SH (ASCP).

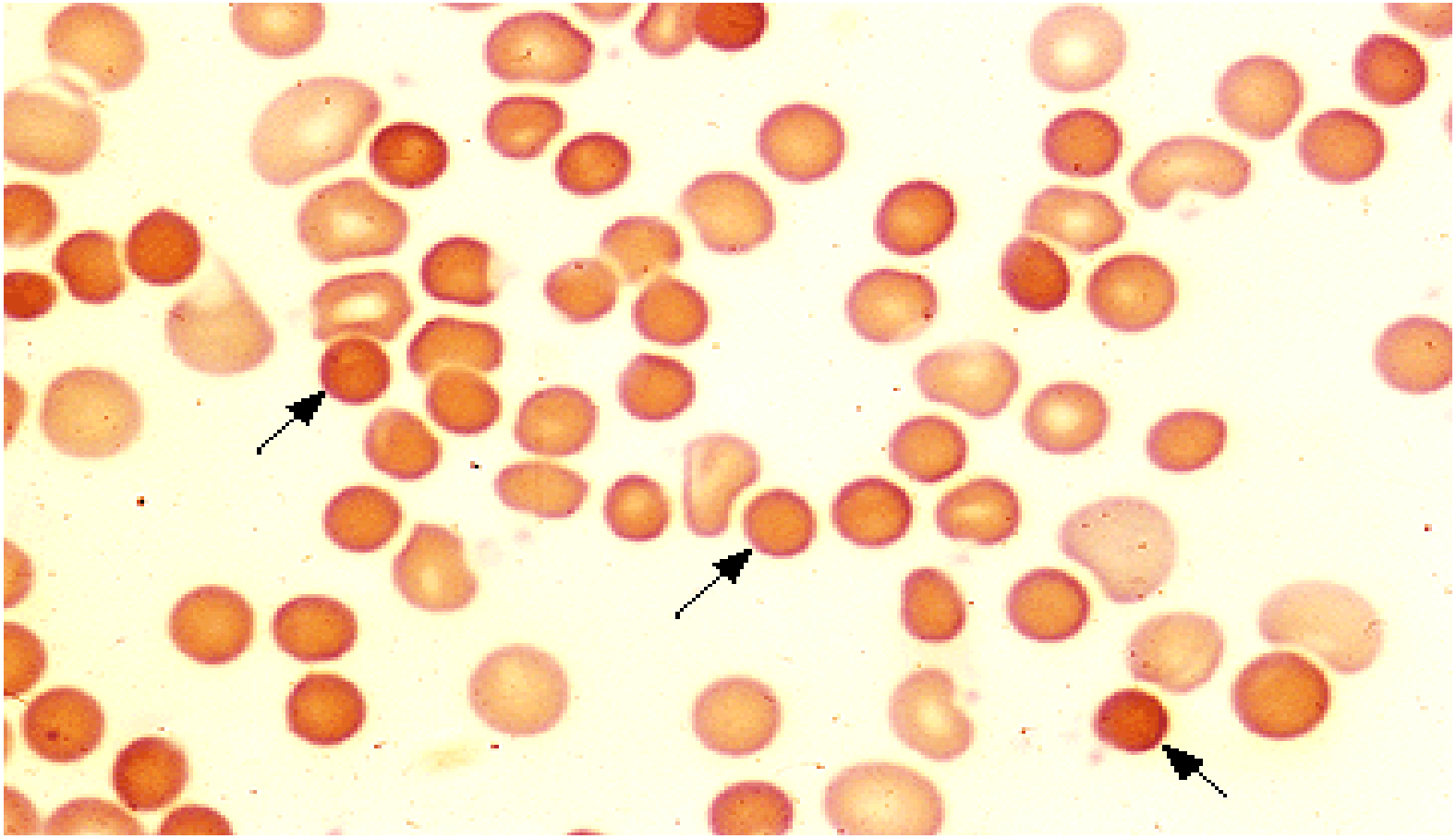

Spherocytes Peripheral blood smear shows multiple spherocytes which are small, dark, dense hyperchromic red cells without central pallor (arrows). These findings are compatible with hereditary spherocytosis or autoimmune hemolytic anemia. Courtesy of Carola von Kapff, SH (ASCP).

- Hastanın eritrosit indeksleri normal olmasına rağmen periferik yaymanın incelenmesi sonucu parçalanmış eritrositlerin görülmesi mikroanjiopatik duruma işaret eder

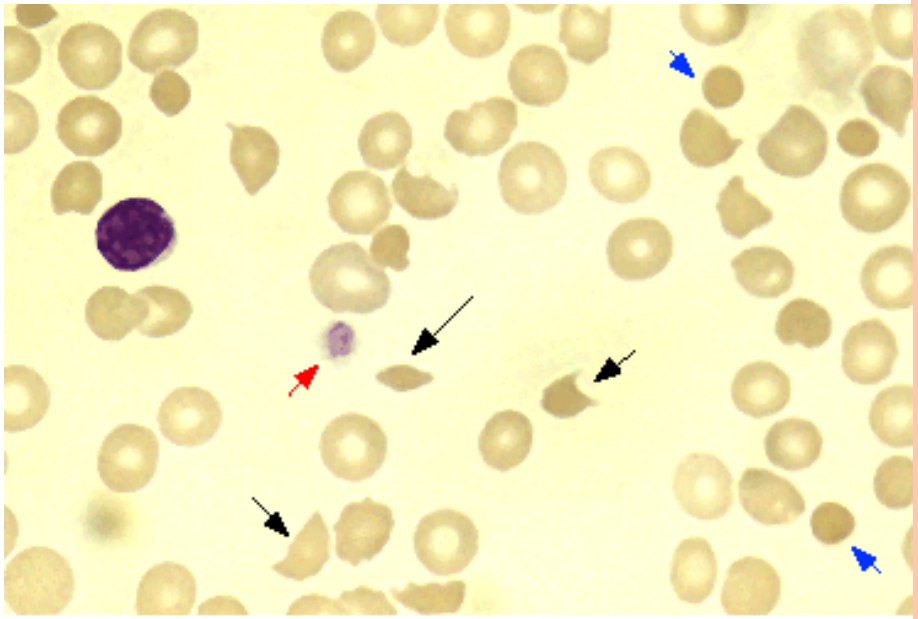

Microangiopathic smear Peripheral blood smear from a patient with a microangiopathic hemolytic anemia with marked red cell fragmentation. The smear shows multiple helmet cells (small arrows), other fragmented red cells (large arrows); the platelet number is reduced and the large platelet in the center (red arrow) suggests that the thrombocytopenia is due to enhanced destruction. Some small spherocytes are also seen (blue arrows). Courtesy of Carola von Kapff, SH (ASCP).

- Konjenital eliptositozda diğer bir morfolojik anomali olan eliptositler görülür

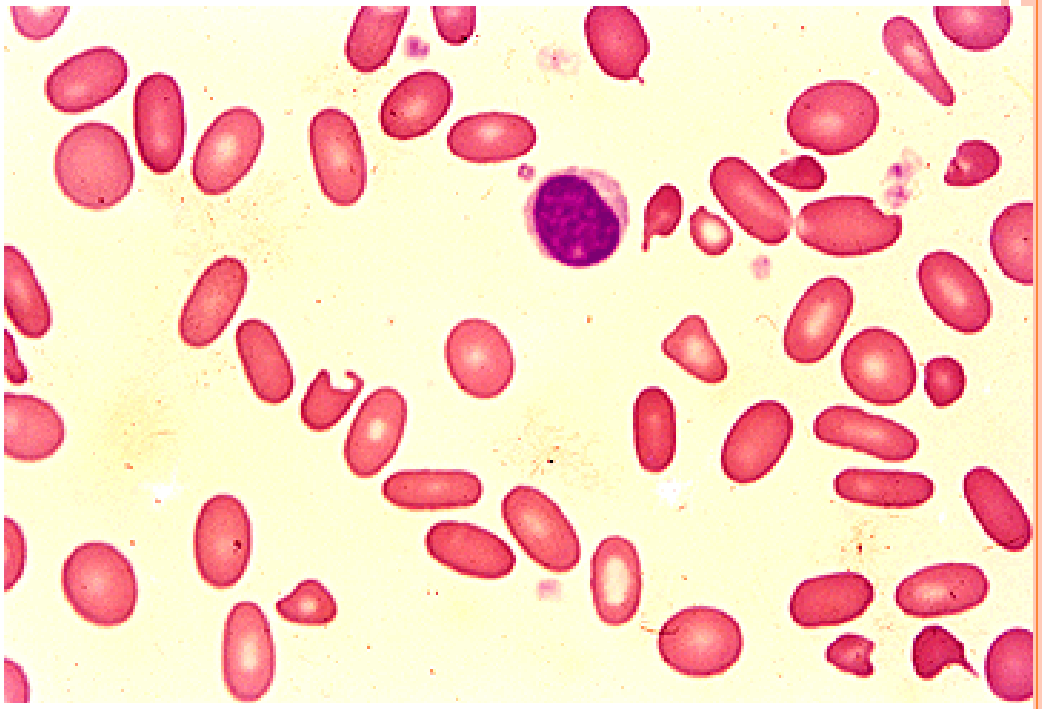

Elliptocytosis Peripheral blood smear from a patient with hereditary elliptocytosis shows multiple elliptocytes. The elliptocytic shape change is thought to result from repeated episodes of elliptocytic deformation that all red cells as they pass through capillary beds. Whereas normal red cells regain a discocytic configuration by a process of elastic recoil, elliptocytic red cells have cytoskeletal abnormalities that impair this recovery process. Courtesy of Carola von Kapff, SH (ASCP).

- Target cell (hedef hücresi) ise çeşitli hemoglobinopatiler de, karaciğer hastalıklarında ve splenektomi sonrası görülür

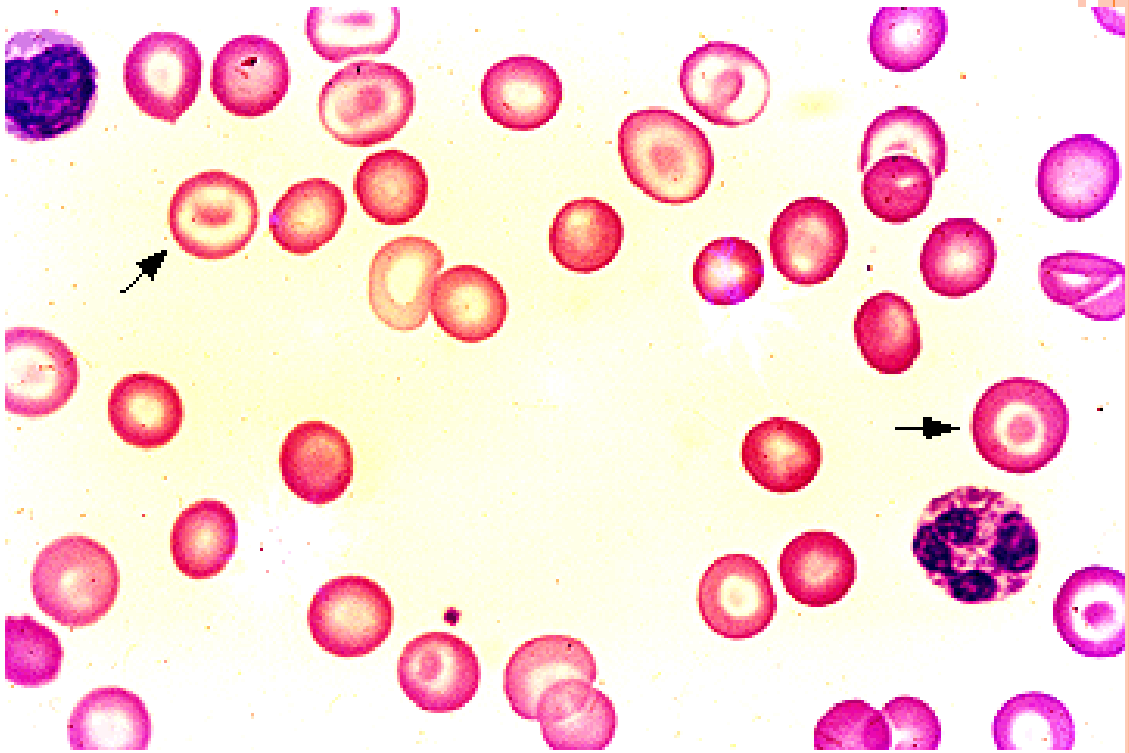

Target cells Peripheral smear shows multiple target cells which have an area of central density surrounded by a halo of pallor (arrows). These cells are characteristic of liver disease and certain hemoglobinopathies (most notably hemoglobin C disease). Courtesy of Carola von Kapff, SH (ASCP).

- Bite cells (ısırılmış hücreler) Heinz body hemolitik anemide görülürler

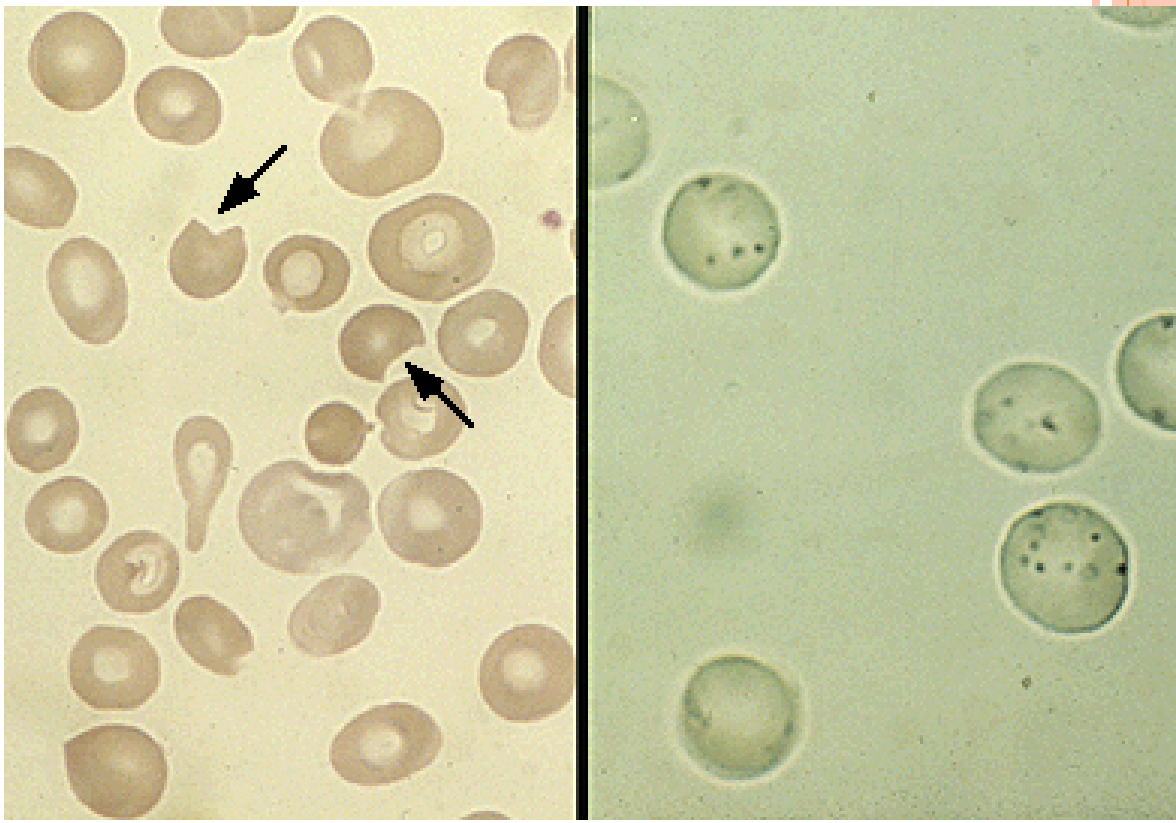

Heinz body hemolytic anemia Split screen view of a peripheral smear from a patient with Heinz body hemolytic anemia. Left panel: red cells with characteristic bite-like deformity (arrows). Right panel: Heinz body preparation which reveals the denatured hemoglobin precipitates. Courtesy of Carola von Kapff, SH (ASCP).

- Fazla sayıda çekirdekli eritrositlerin periferde görülmesi hızlı kemik iliği döngüsünü gösterir ve hemolitik bir sürece işaret eder

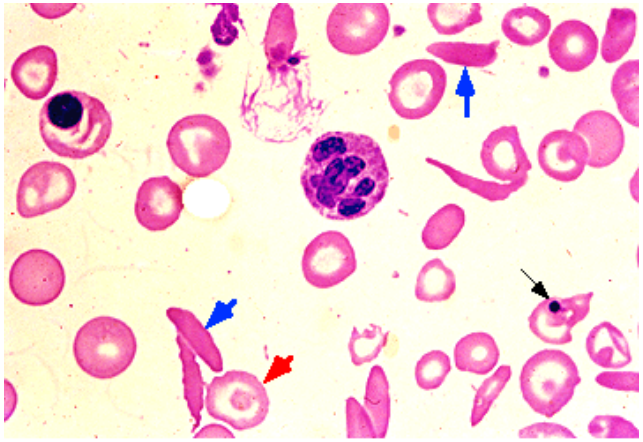

Sickle cell anemia Peripheral smear from a patient with sickle cell anemia shows multiple spindly sickle cells (blue arrows), a nucleated red blood cell in the upper left, and a Howell-Jolly body (black arrow), which is a nuclear fragment normally removed by the spleen. Target cells are also present (red arrow). This patient has functional asplenia because of repeated splenic infarctions. Courtesy of Carola von Kapff, SH (ASCP).

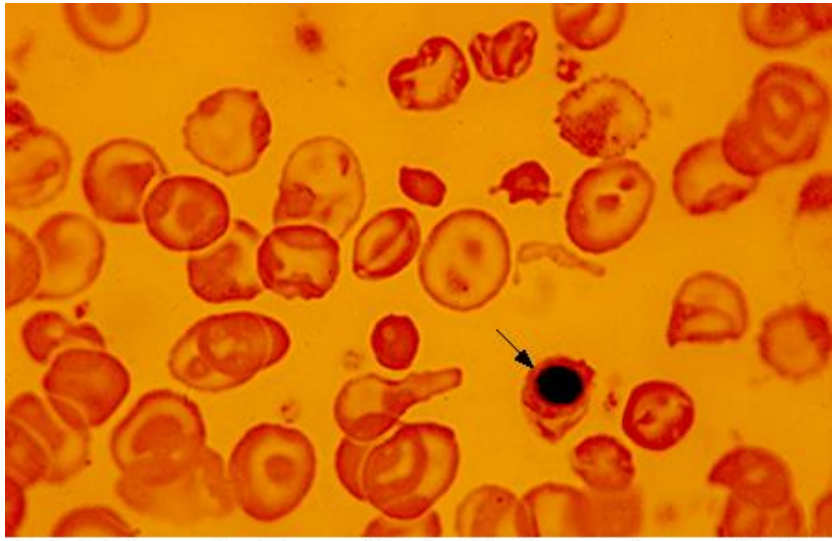

Beta thalassemia intermedia Peripheral smear from a patient with beta thalassemia intermedia post-splenectomy. This field shows target cells, hypochromic cells, microcytic cells, red cell fragments, red cells with bizarre shapes, and a single nucleated red cell (arrow). Courtesy of Stanley Schrier, MD.

Cold agglutinin disease - 2.

Agglutinated masses of RBCs of variable size are noted in this view. Both the WBC and platelet count were normal.

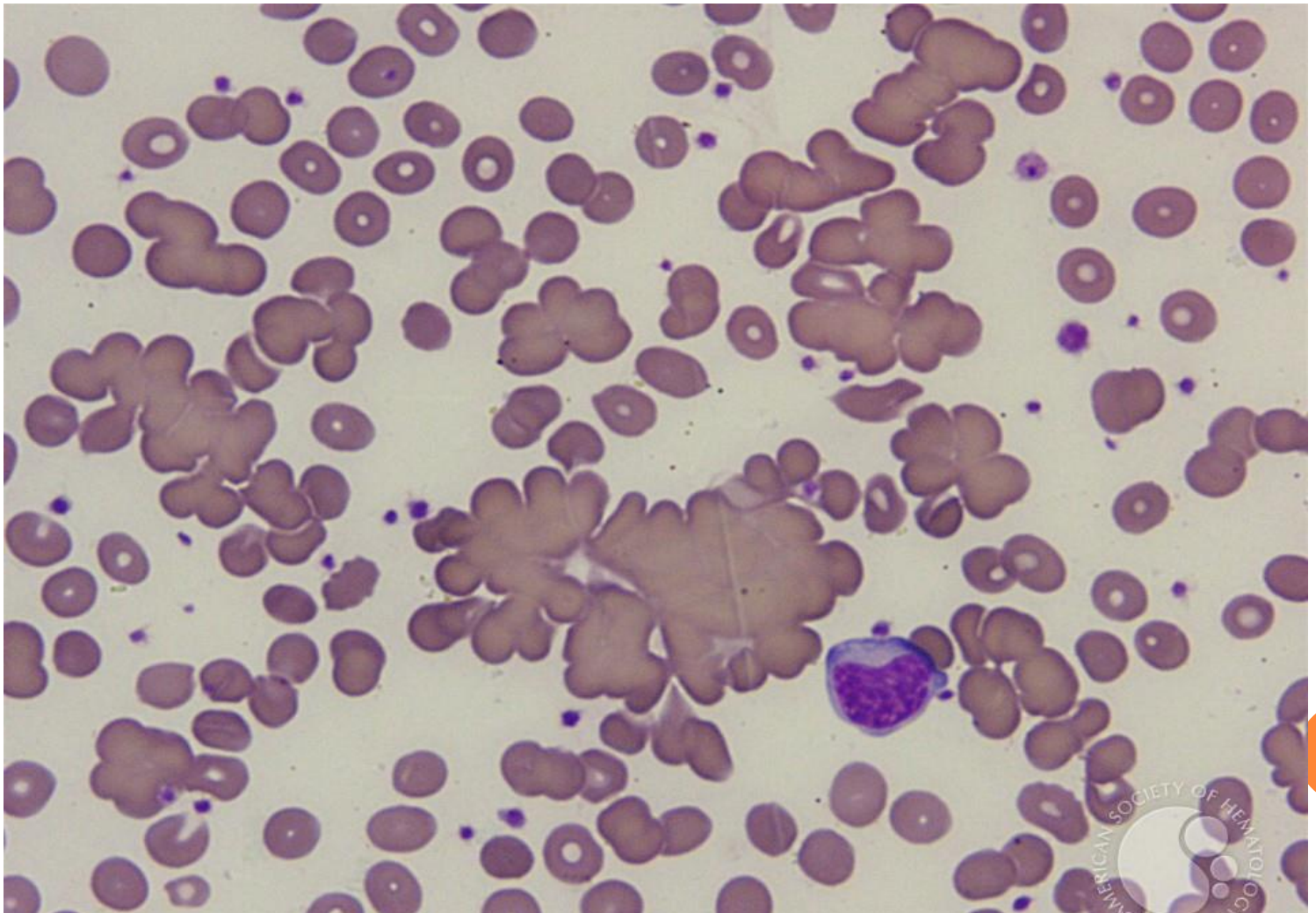

Erythroblastosis Fetails - 2.

Spherocytes are present (arrows).

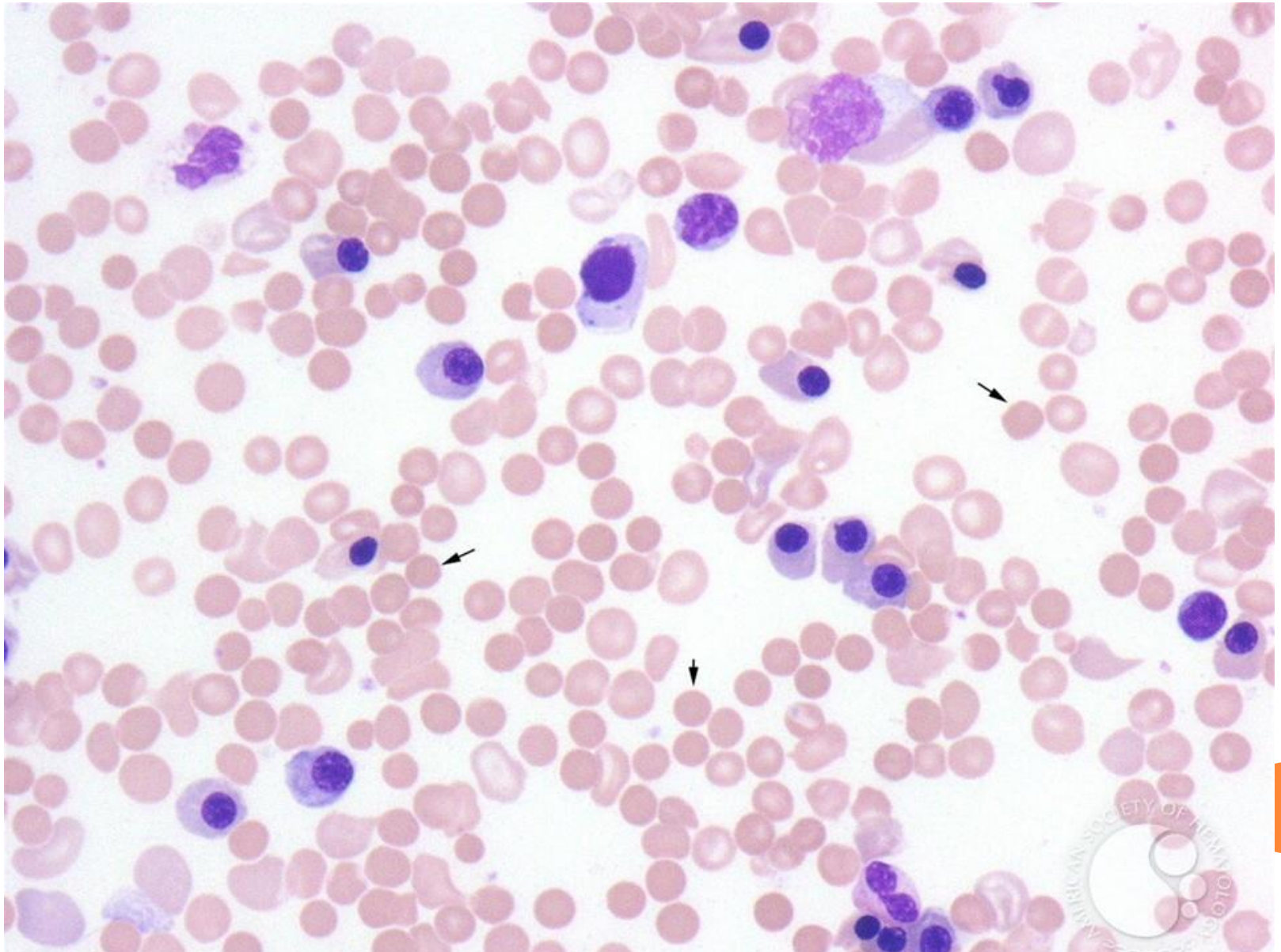

Blister cell - 1.

Characteristic "blister" RBCs (large arrow) noted in patients with G6PD deficiency are present on this peripheral smear. . The pale blue/gray cells (small arrow) are reticulocytes that are increased in response to the hemolytic anemia.

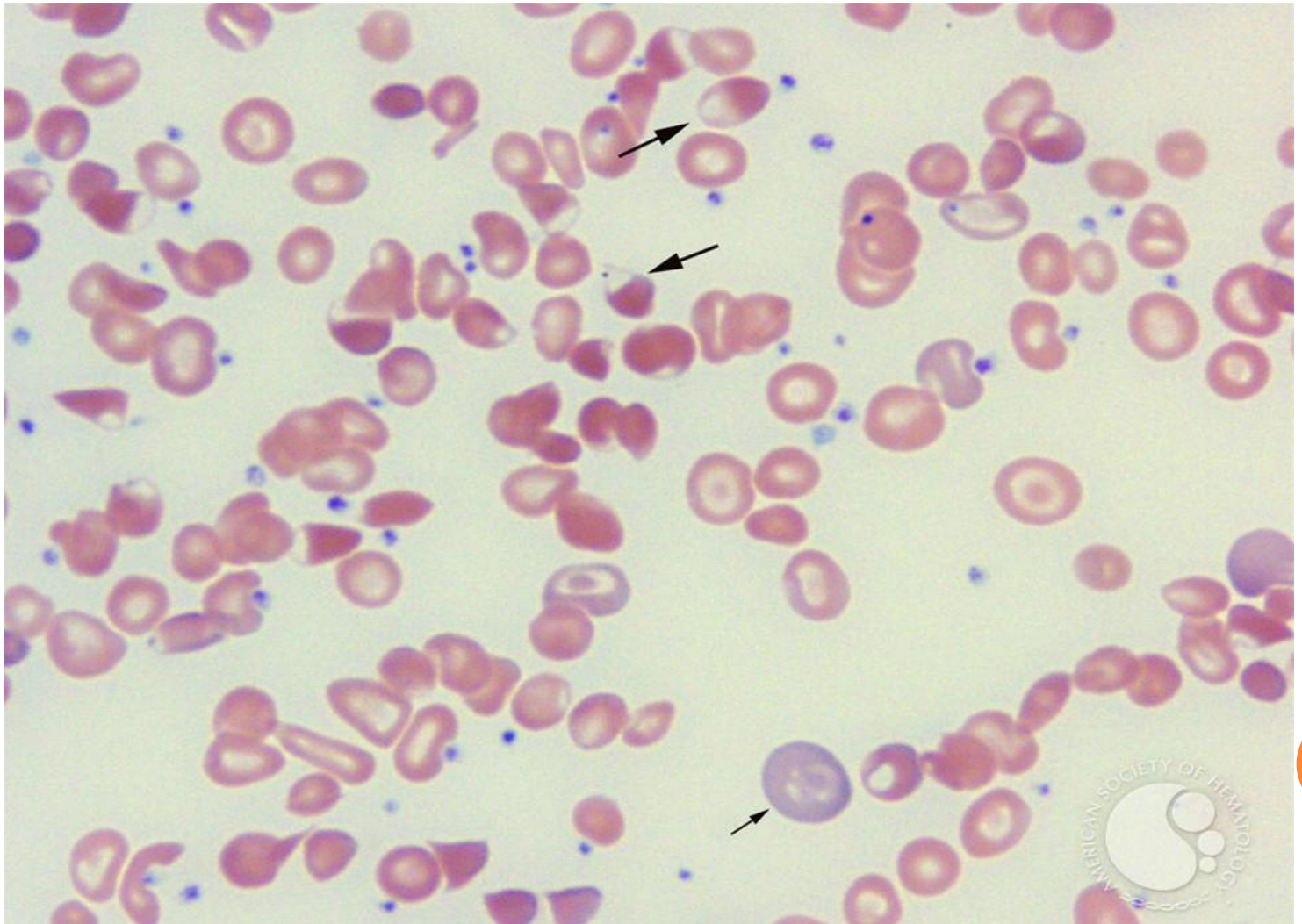

Myelodysplastic Syndrome: Myelodysplastic Syndrome Associated with Isolated del(5q)Chromosome Abnormality ('5q- Syndrome') - 8.

This figure summarizes the characteristic findings associated with MDS with an isolated del(5q) syndrome. The peripheral blood often shows a macrocytic anemia with normal or elevated platelet counts, and the bone marrow biopsy and aspirate are characterized by the finding of megakaryocytes with monolobated or hypolobated nuclei.

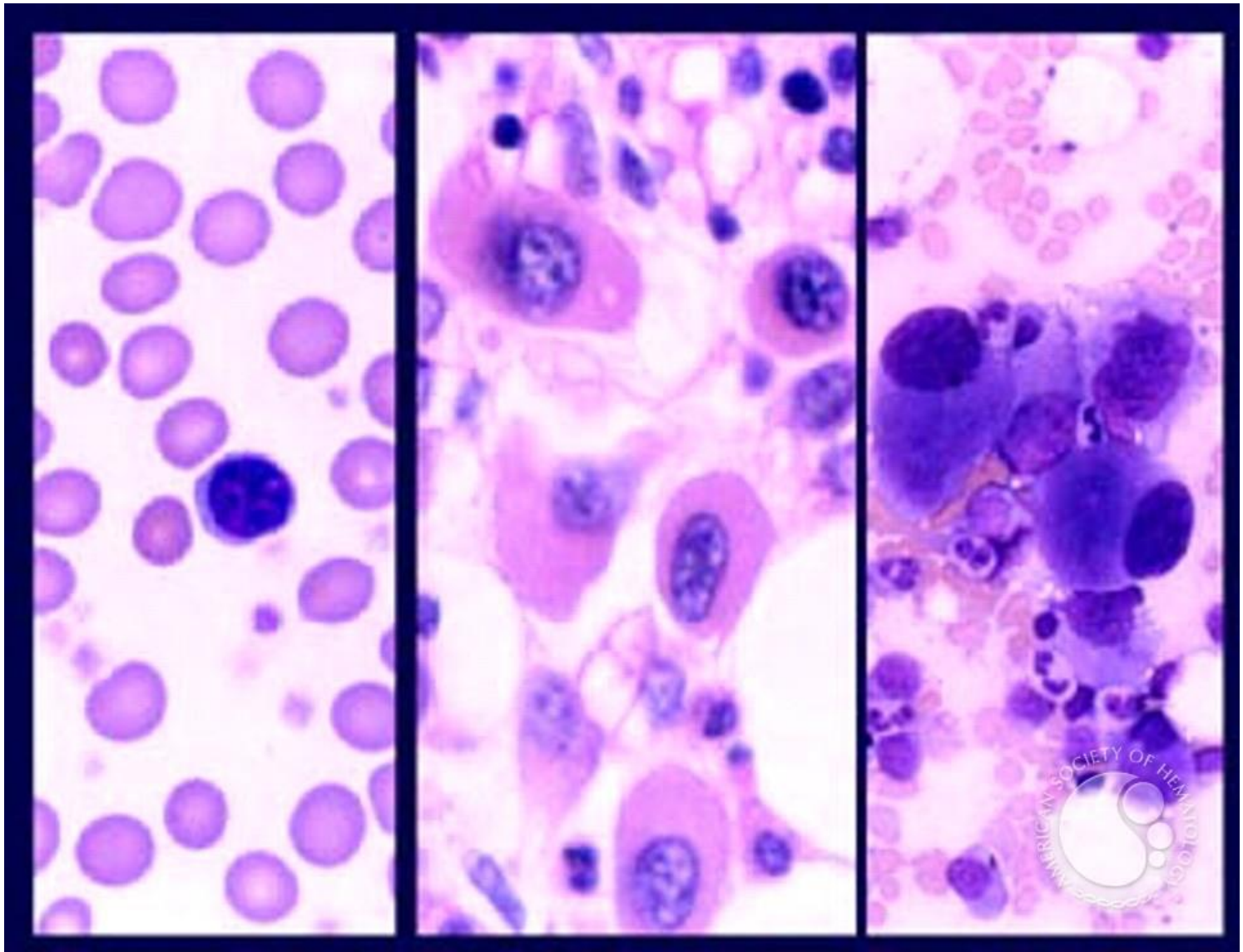

Howell-Jolly bodies - 1.

Howell-Jolly bodies are red cell inclusions which are residual nuclear fragments. They may be seen in hemolysis, megaloblastic anemia, or post-splenectomy

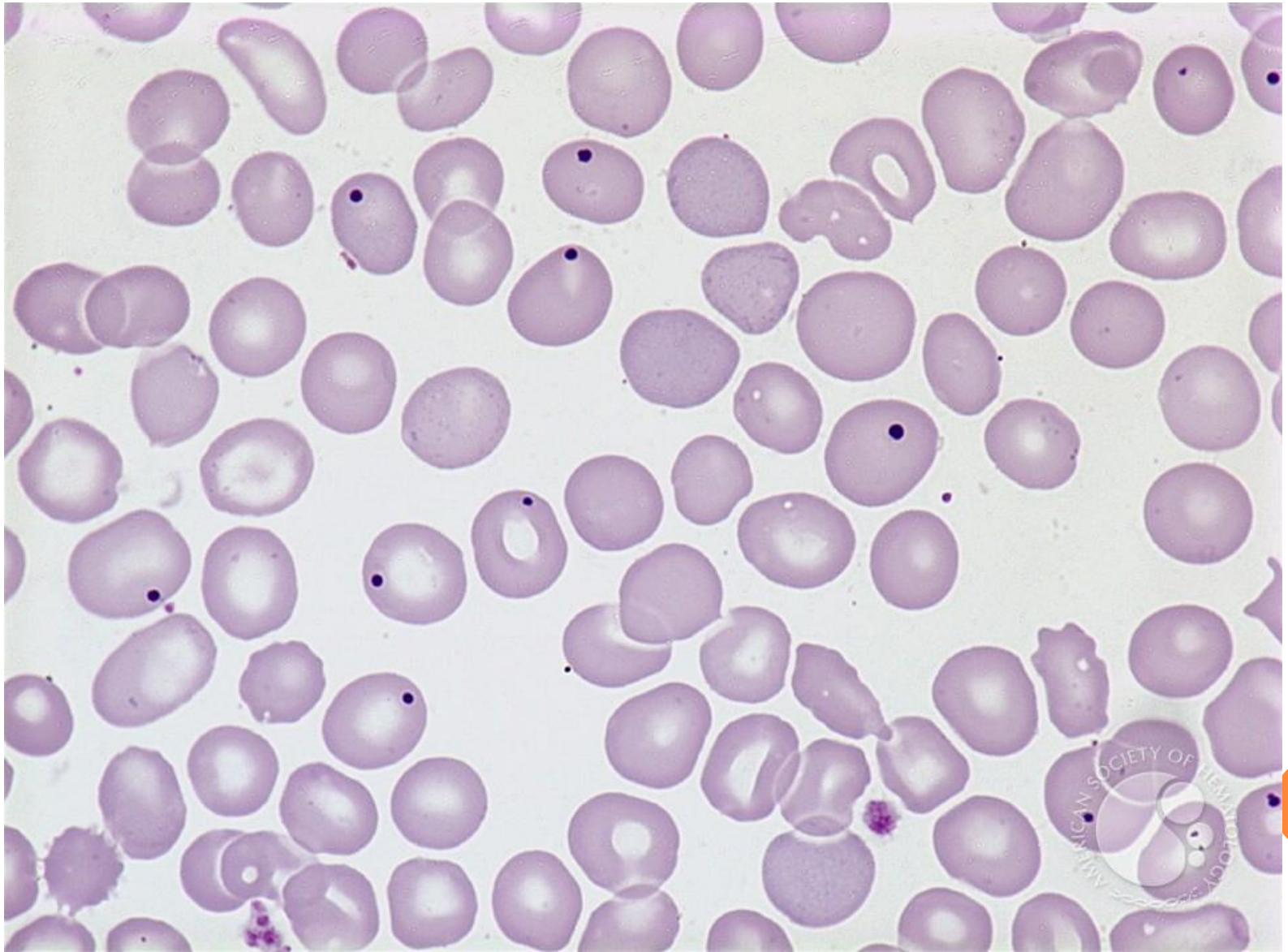

Multiparameter flow cytometry analysis of peripheral blood in PNH
(A-D) Aplastic anemia patient with small (2%) PNH clone; (E-H) classic PNH patient. (A,E) Forward scatter (FSC)/side scatter (SSC) display showing initial gate to exclude lymphocytes and debris. (B,F) Granulocytes (green) are identified as bright CD15 and low CD33, whereas monocytes (blue) are bright CD33 and low CD15. (C,G) Population of GPI anchor protein–deficient granulocytes showing lack of staining with both anti-CD24 and FLAER. (D,H) Population of GPI anchor protein–deficient monocytes showing lack of staining with both anti-CD14 and FLAER.

Itiparameter flow cytometry analysis of peripheral blood in PNH. (A-D) Aplastic anemia patient with small (2%) PNH clone; (E-H) classic PNH patient.

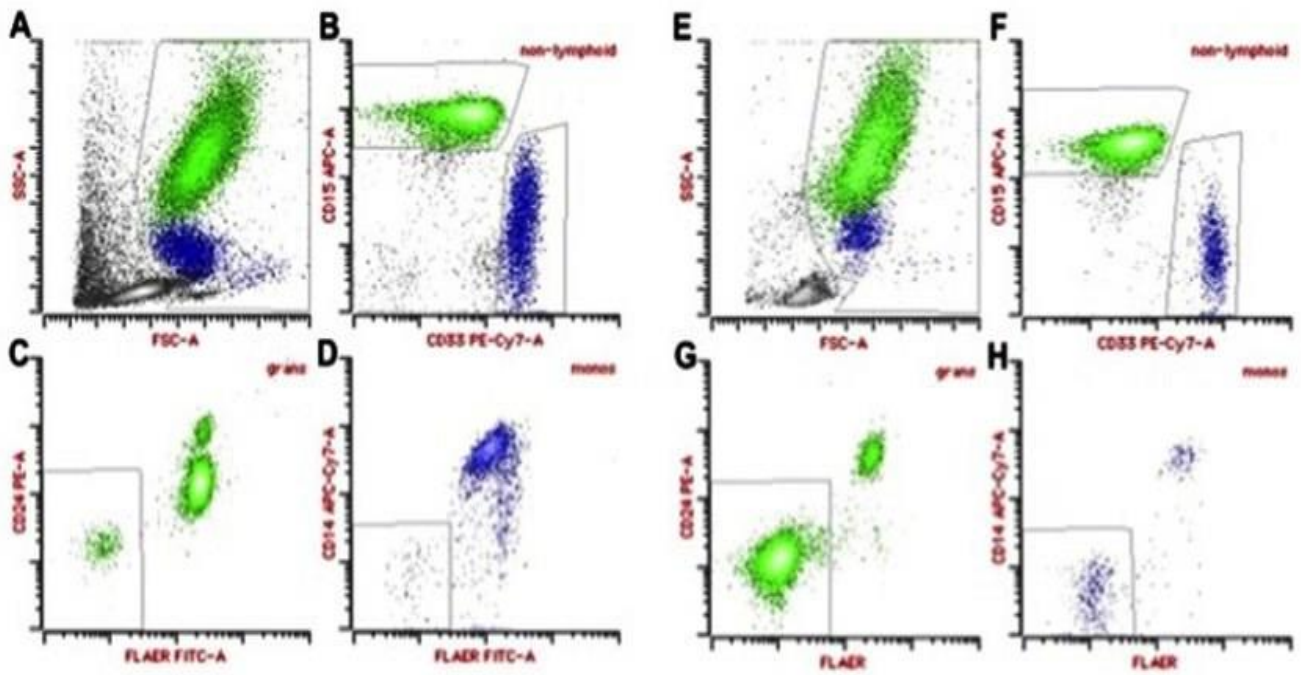

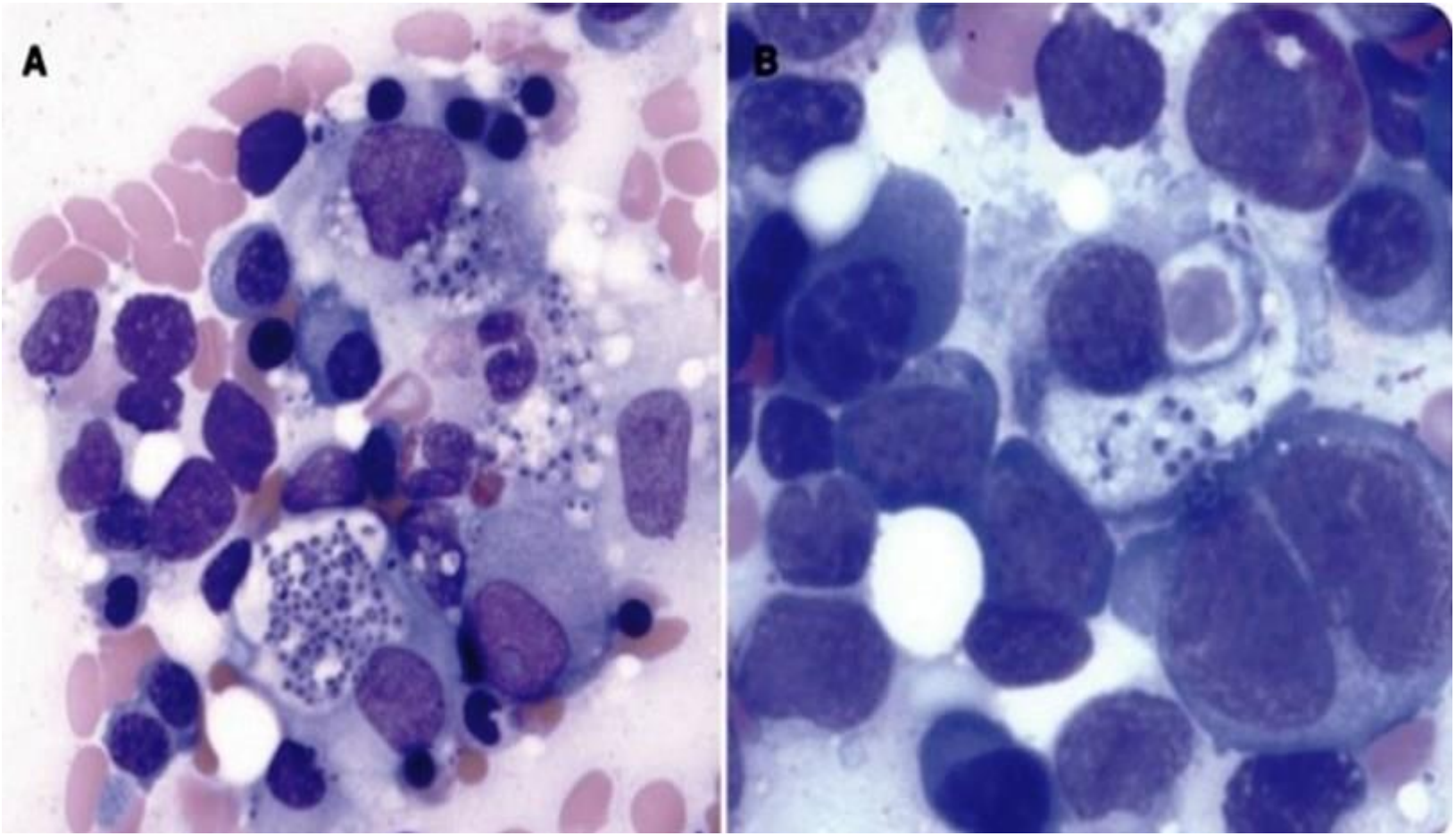

Hemophagocytic lymphohistiocytosis and disseminated histoplasmosis

Doublet spherocytes

A 55-year-old woman presented with progressive fatigue, jaundice, and weight loss of 40 pounds. Physical examination revealed scleral icterus, axillary lymphadenopathy, and splenomegaly. Laboratory values showed a white blood cell count of 11?200/µL, hemoglobin 6.3 g/dL, hematocrit 18.3%, platelets 116 K/µL, haptoglobin <5.8 mg/dL, reticulocyte count 18.6%, mean corpuscular volume 131 fl, and indirect hyperbilirubinemia. Direct Coombs test was positive for immunoglobulin G (IgG) with no evidence for IgM. Peripheral smear revealed that 12% of discrete stained entities were doublets (arrows). Remarkably, there were no single spherocytes. Typically, normal smears show only rare doublets (<1%). There was no evidence of underlying lymphoproliferative disorder. Diagnosis was warm antibody autoimmune hemolytic anemia and thrombocytopenia (Evan syndrome). The patient relapsed after prednisone, rituximab, and splenectomy and eventually responded to azathioprine. With treatment, her mean corpuscular volume returned to normal along with disappearance of spherocytes. Spherocytosis is a feature of autoimmune hemolytic anemias and results from partial phagocytosis of IgG/complement-coated erythrocytes. Doublet formation has only rarely been described previously. No triplets or larger aggregates were present is this case, but have been previously reported.

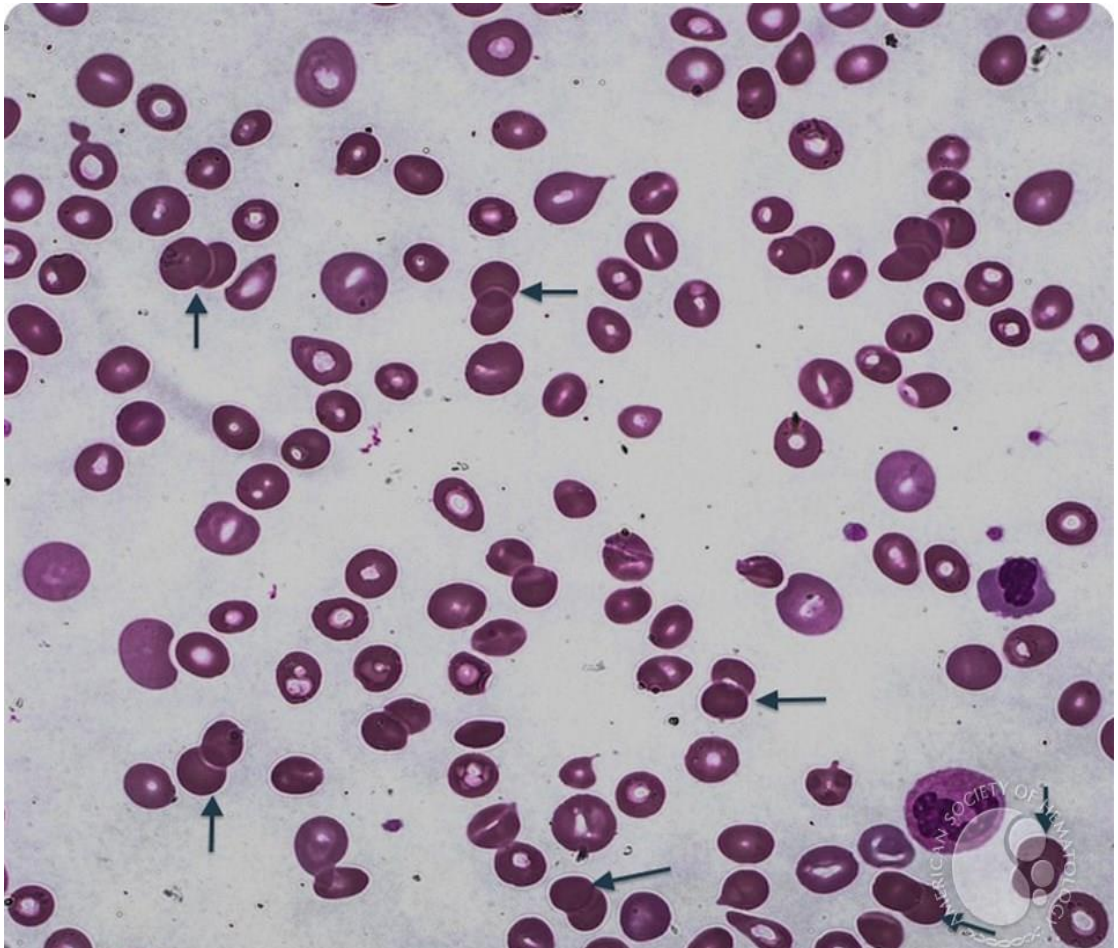

Basophilic Stippling - 3.

Coarse dense basophilic stippling of several RBCs is shown in this view. Basophilic stippling can be seen in a variety of hematologic disorders including the thalassemias; heavy metal poisoning, particularly lead or arsenicals; dyserythropoietic anemias; megaloblastic anemia; and pyrimidine 5′-nucleotidase deficiency.

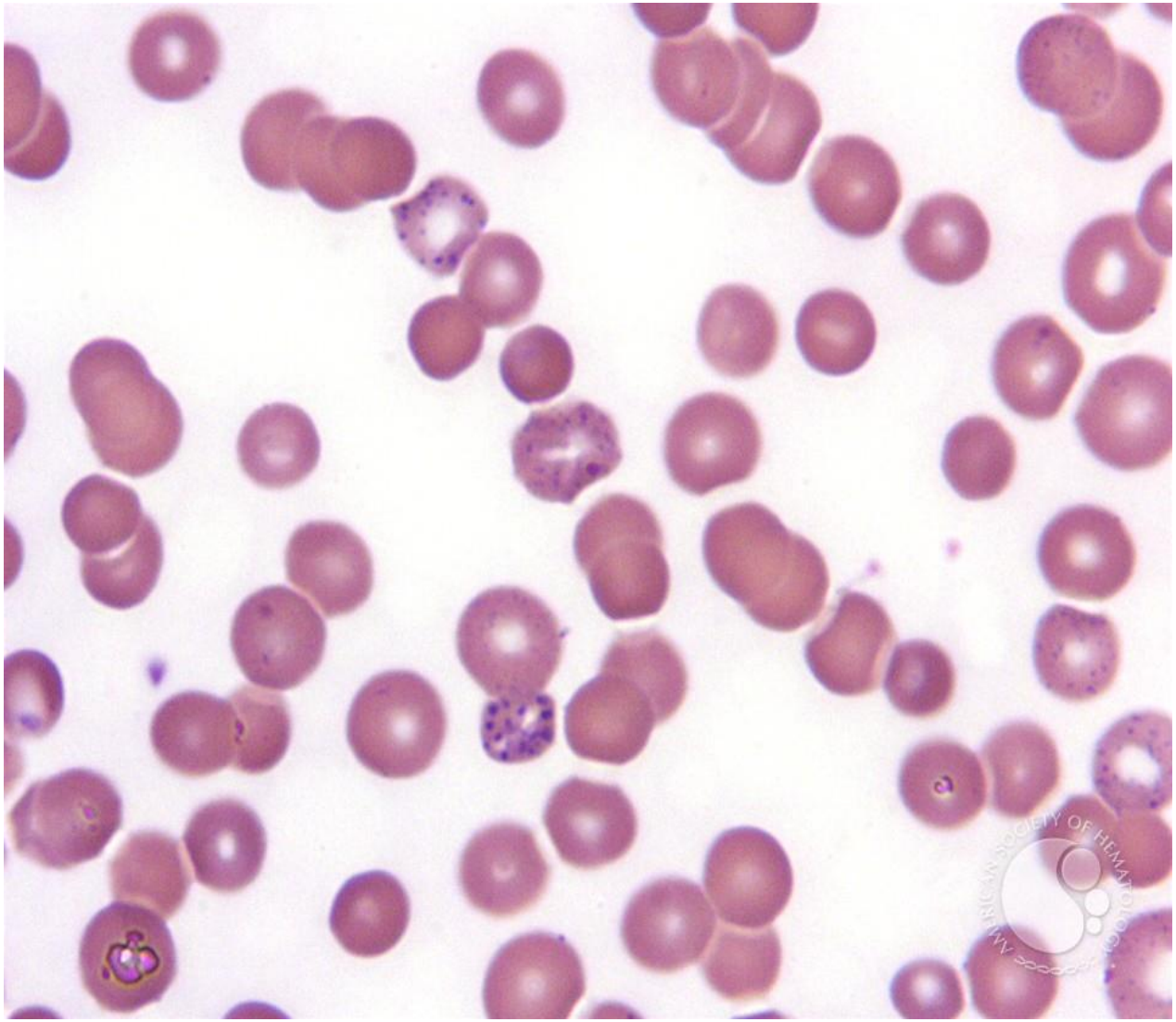

Hemolytic disease of the newborn secondary to ABO incompatibility - 1.

Peripheral smear from a full-term newborn with hemolytic anemia due to ABO incompatibility. Mother's blood type was O^+ while the newborn's was A^+. Note the increased number of spherocytes in addition to the polychromatophilic cells and bi-nucleated RBC. The DAT was weakly positive.

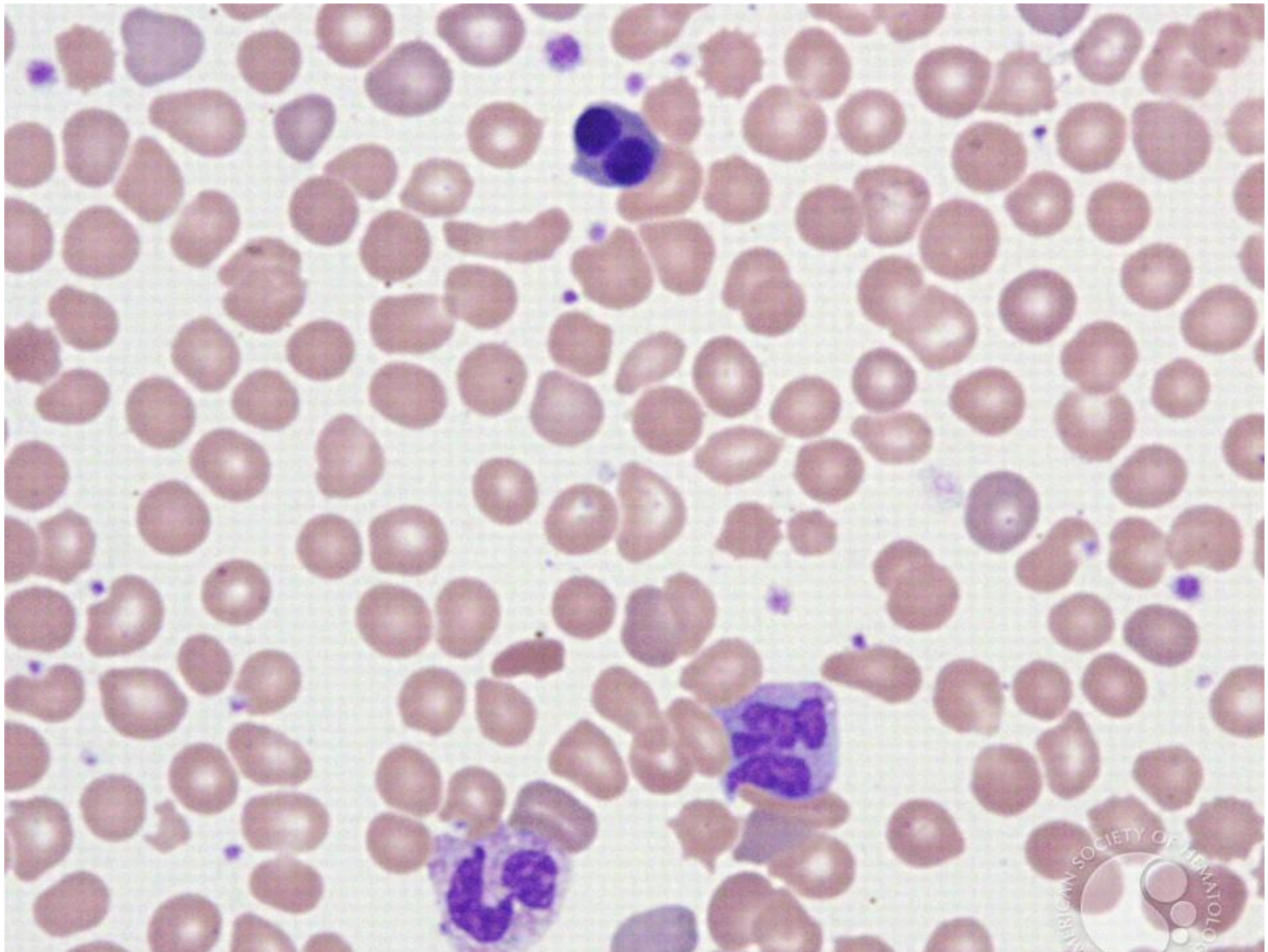

Severe vitamin B12 deficiency mimicking thrombotic thrombocytopenic purpura

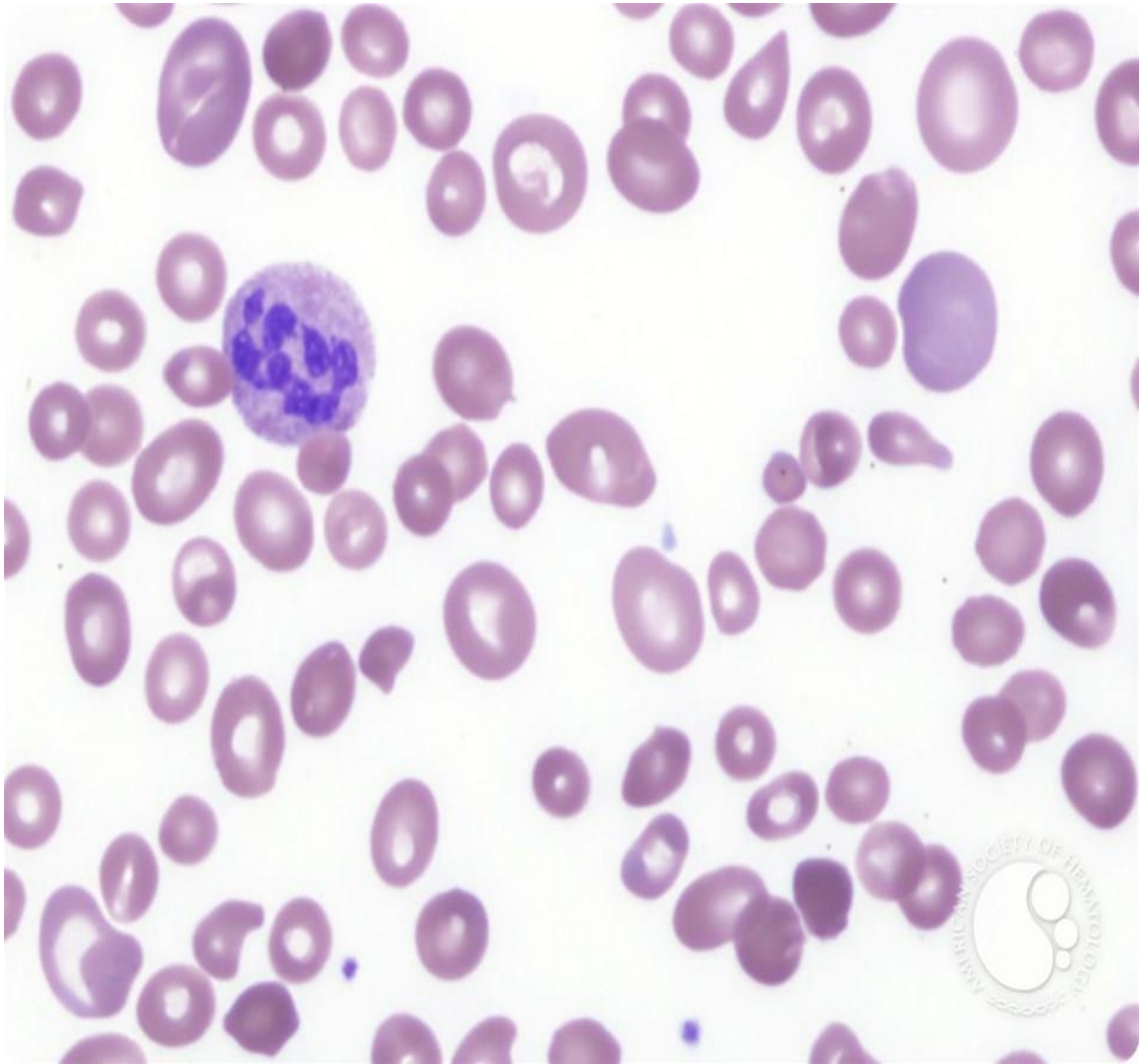

Cold agglutinin disease with PLL

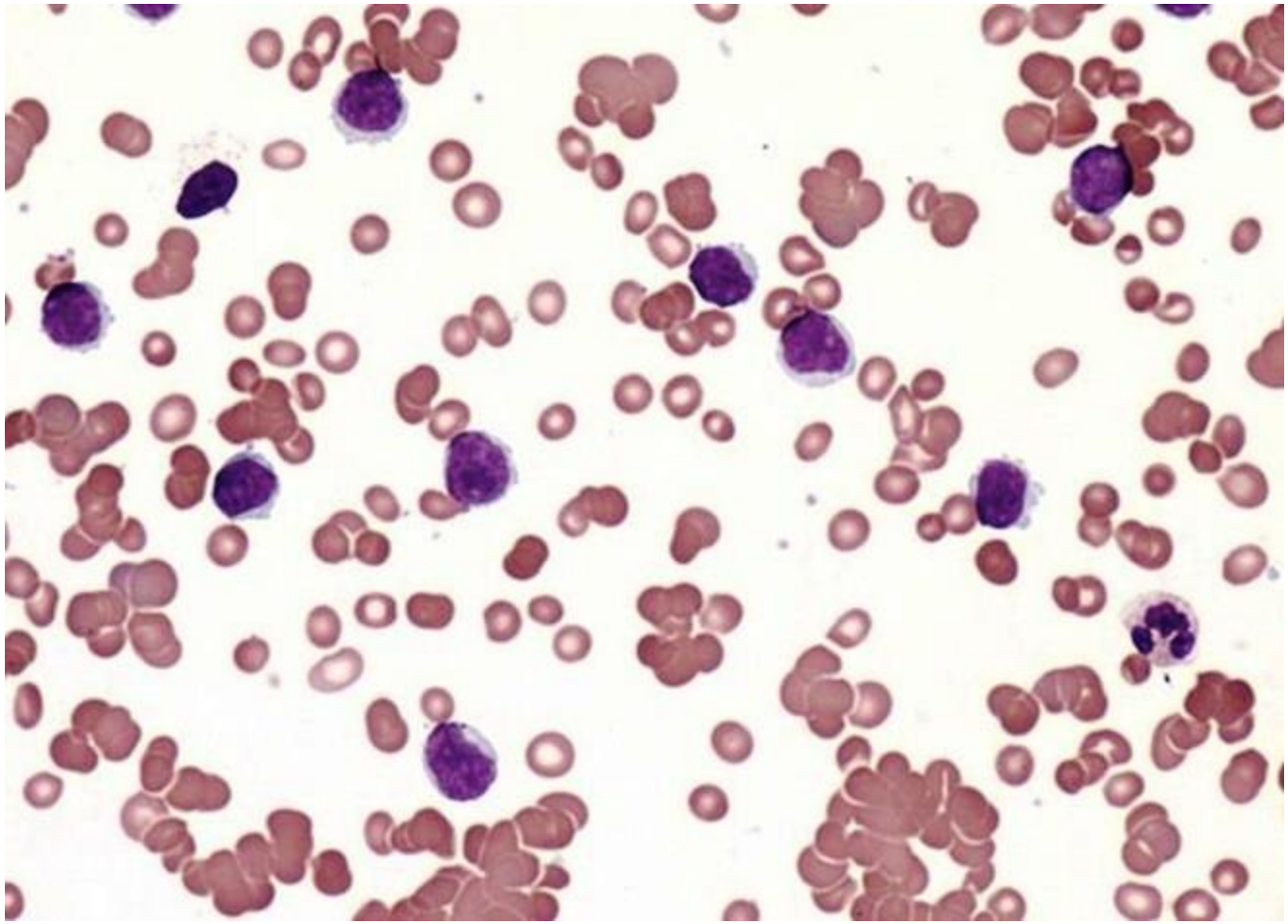

Plasmodium falciparum infection - 1.

A 49-year-old African-American male presented to the ED with complaint of diarrhea, fever, and myalgia. The patient had traveled to Ghana one week prior to presentation. The CBC was remarkable for a normochromic normocytic anemia (hemoglobin = 11.9g/dl) with marked thrombocytopenia (platelet count = 20K/ul). Total and direct bilirubin and LDH were elevated at 3.3 mg/dL, 1.4 mg/dL, and 629 IU/L, respectively. Haptoglobin was decreased at 6.0 g/dL consistent with hemolytic anemia. The PT and PTT were within normal limits ruling out disseminated intravascular coagulation as the cause of the thrombocytopenia. The peripheral blood smear showed red cell inclusions with ~10% parasitemia.

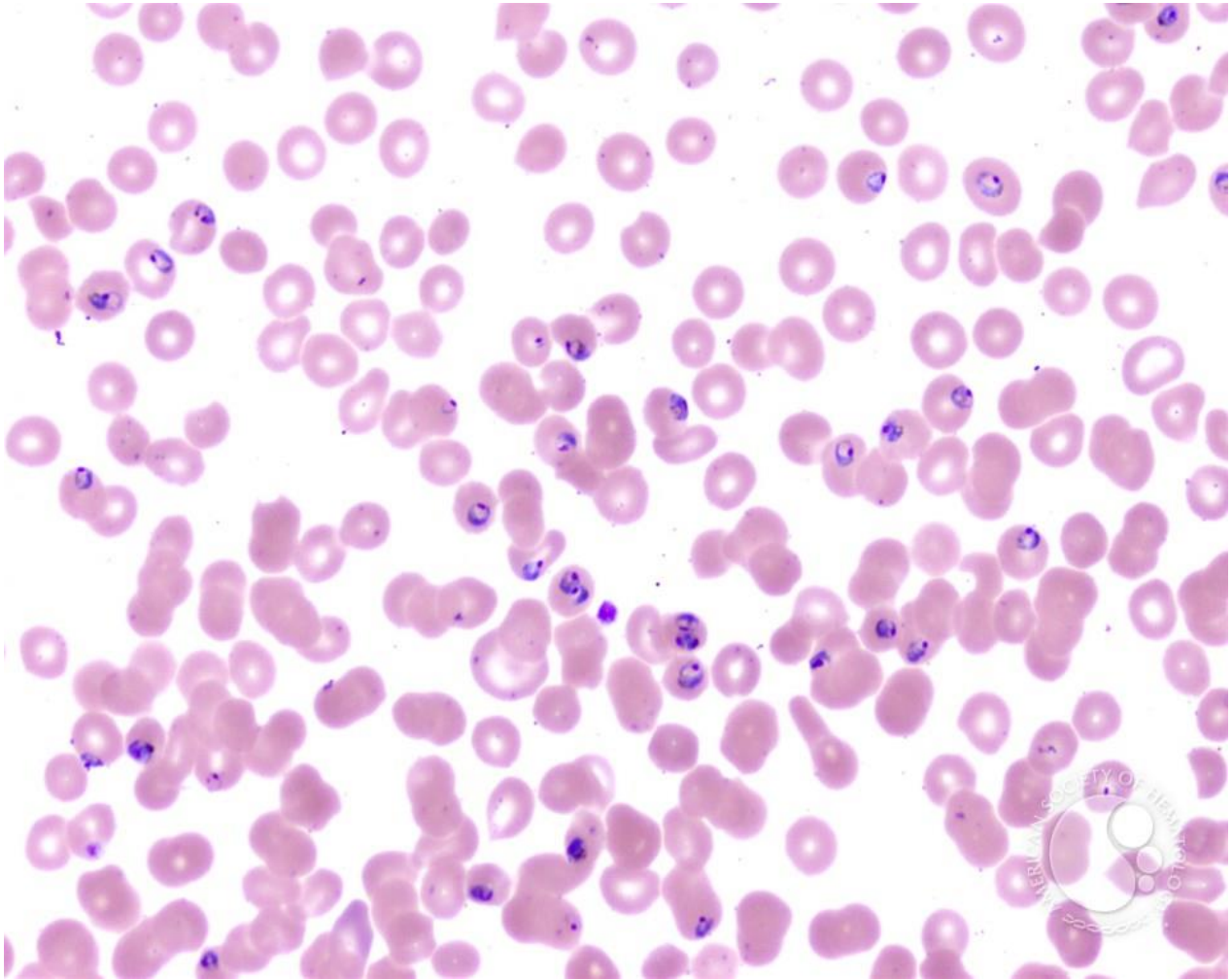

Hereditary elliptocytosis

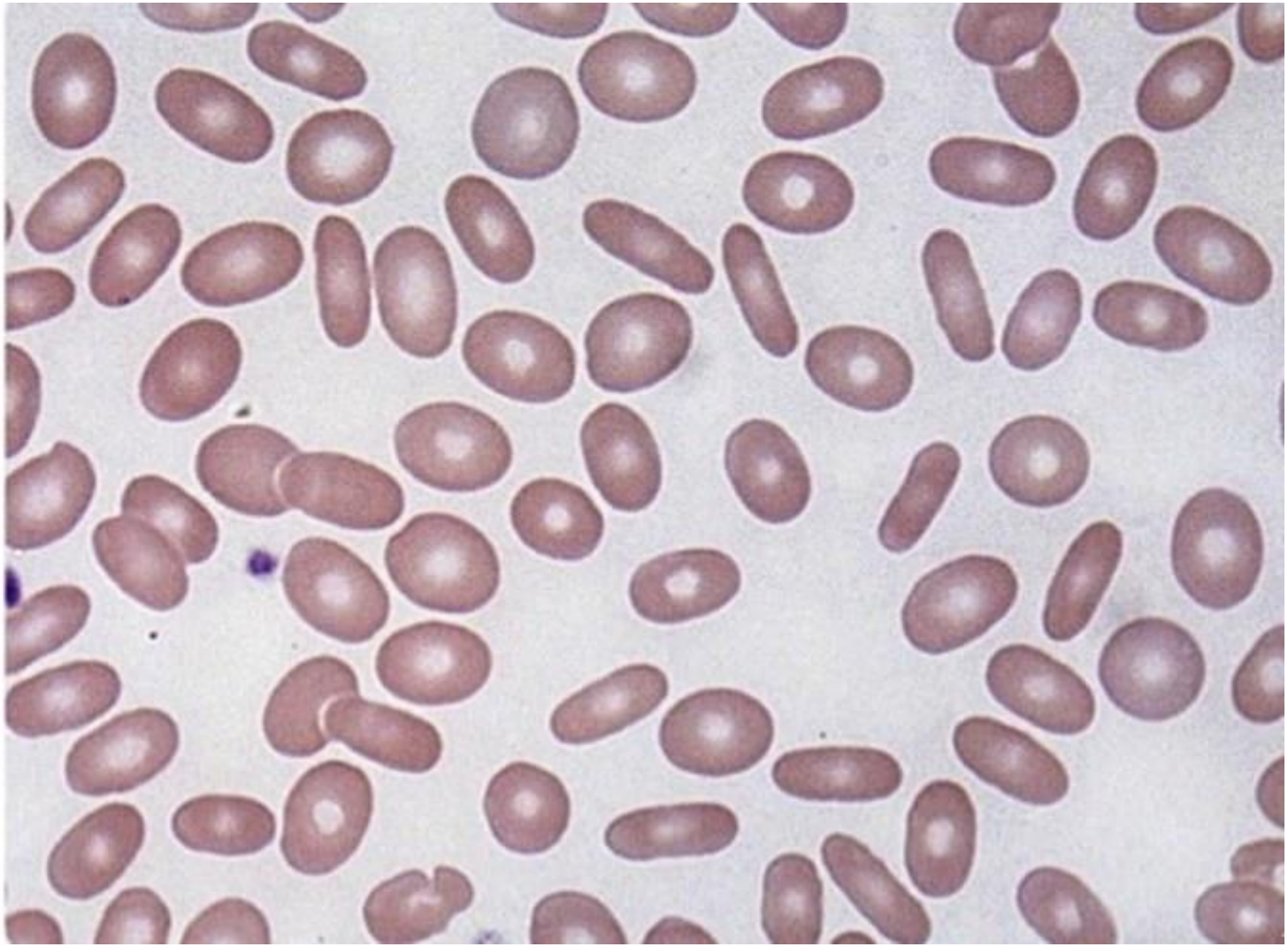

Benzene induced aplastic anemia

The patient presented with sepsis (common presentation) and was found to have pancytopenia. The patient worked in a small manufacturing business cleaning parts using benzene containing solvents in an unventilated room. The physical examination showed pallor and petechiae. The liver, spleen, and lymph nodes were not enlarged. Examination of the peripheral blood smear showed that the red blood cells were normocytic with markedly reduced reticulocytes. The bone marrow was profoundly hypocellular with a decrease in all elements; the marrow space is composed mostly of fat cells and marrow stroma. Hematopoietic cells were morphologically normal

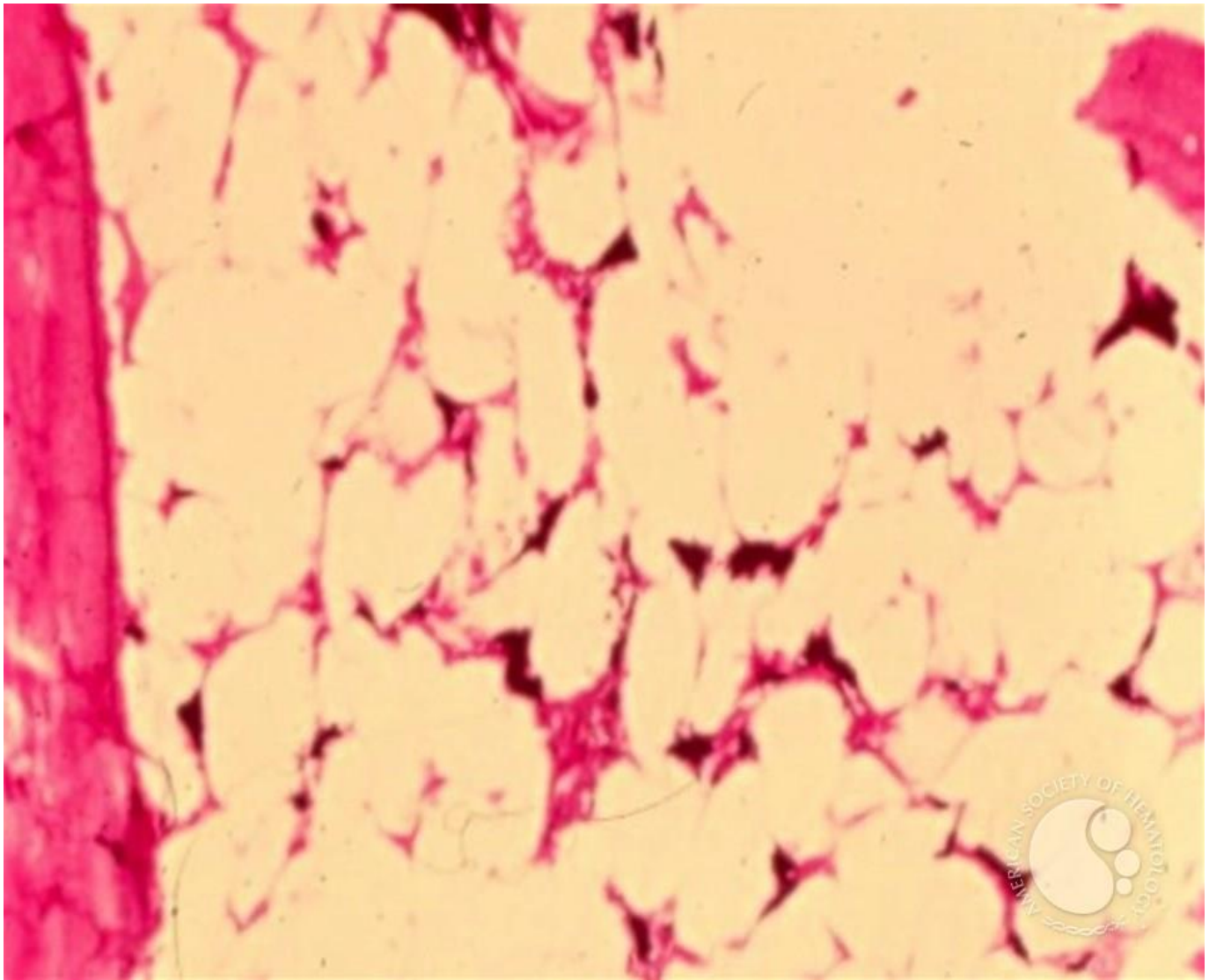

Microangiopathic hemolytic anemia - 2.

Schistocytes (arrow) have an irregular shape and lack the area of central pallor usually seen in erythrocytes.

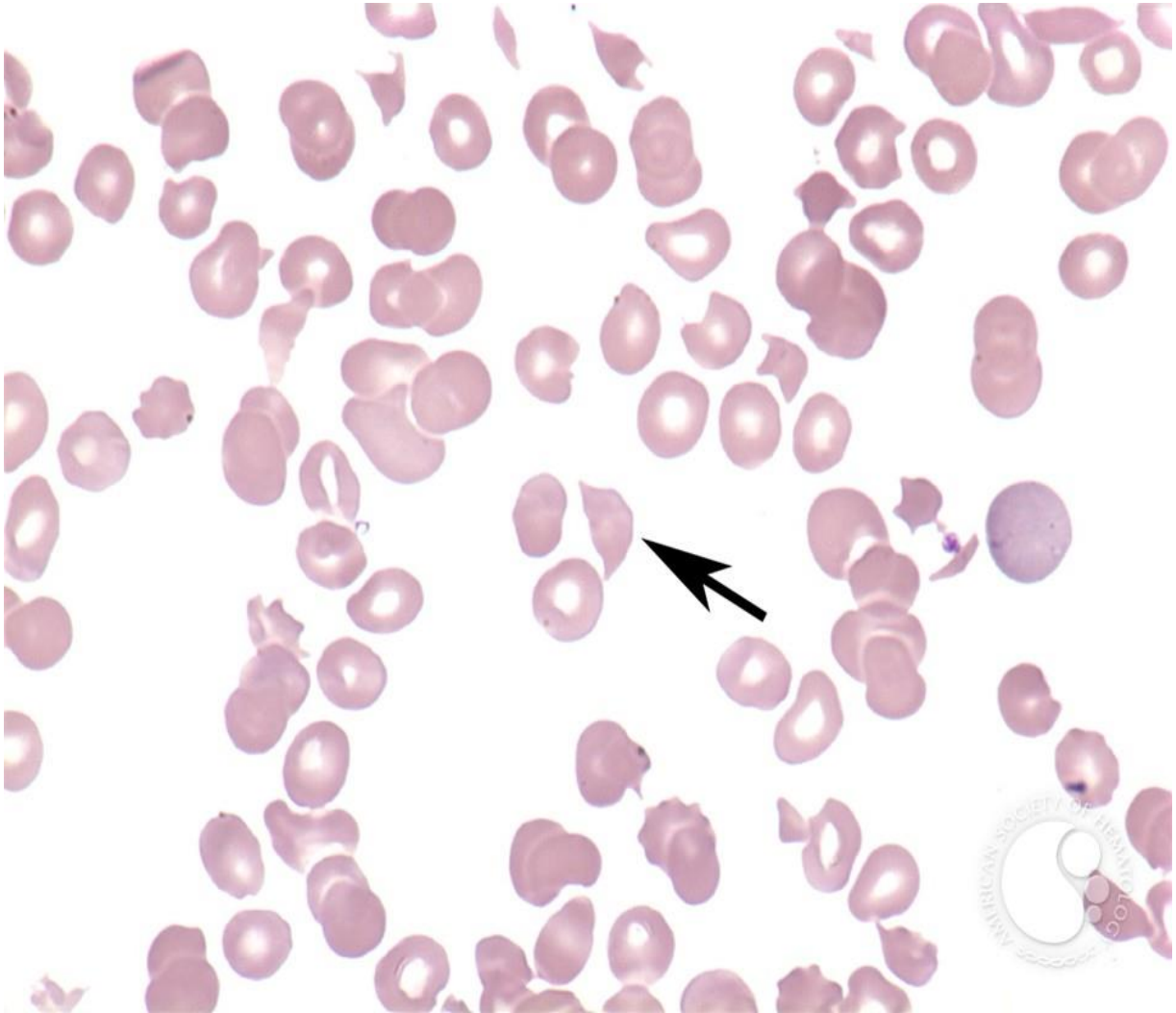

Spur Cell Anemia – 2.

Peripheral smear on a 49 year old male with history of alcoholic cirrhois who had a sudden drop in hemoglobin associated with worsening jaundice. RBCs with spike like projections (spur cells), target cells and RBC fragments are prominent. (W-G 50x)

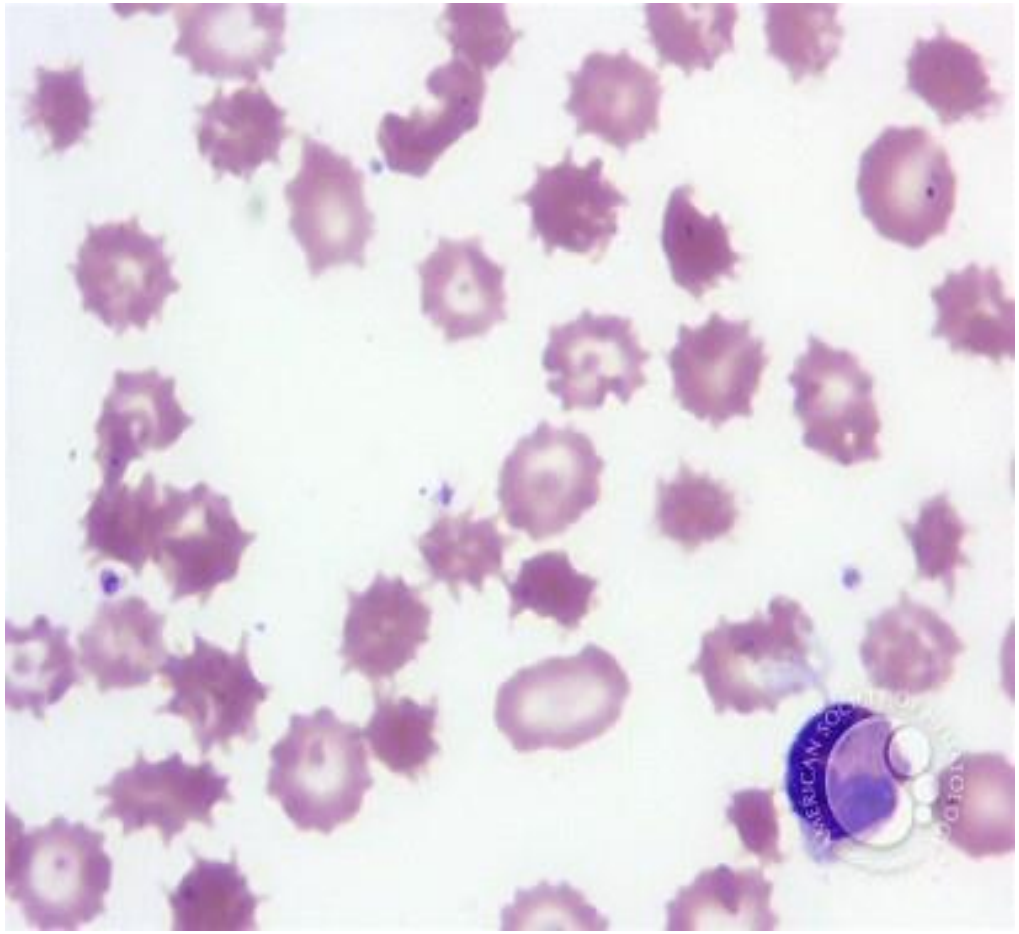

Pernicious Anemia - 2.

Note the hypersegmented neutrophil (7-8 lobes).

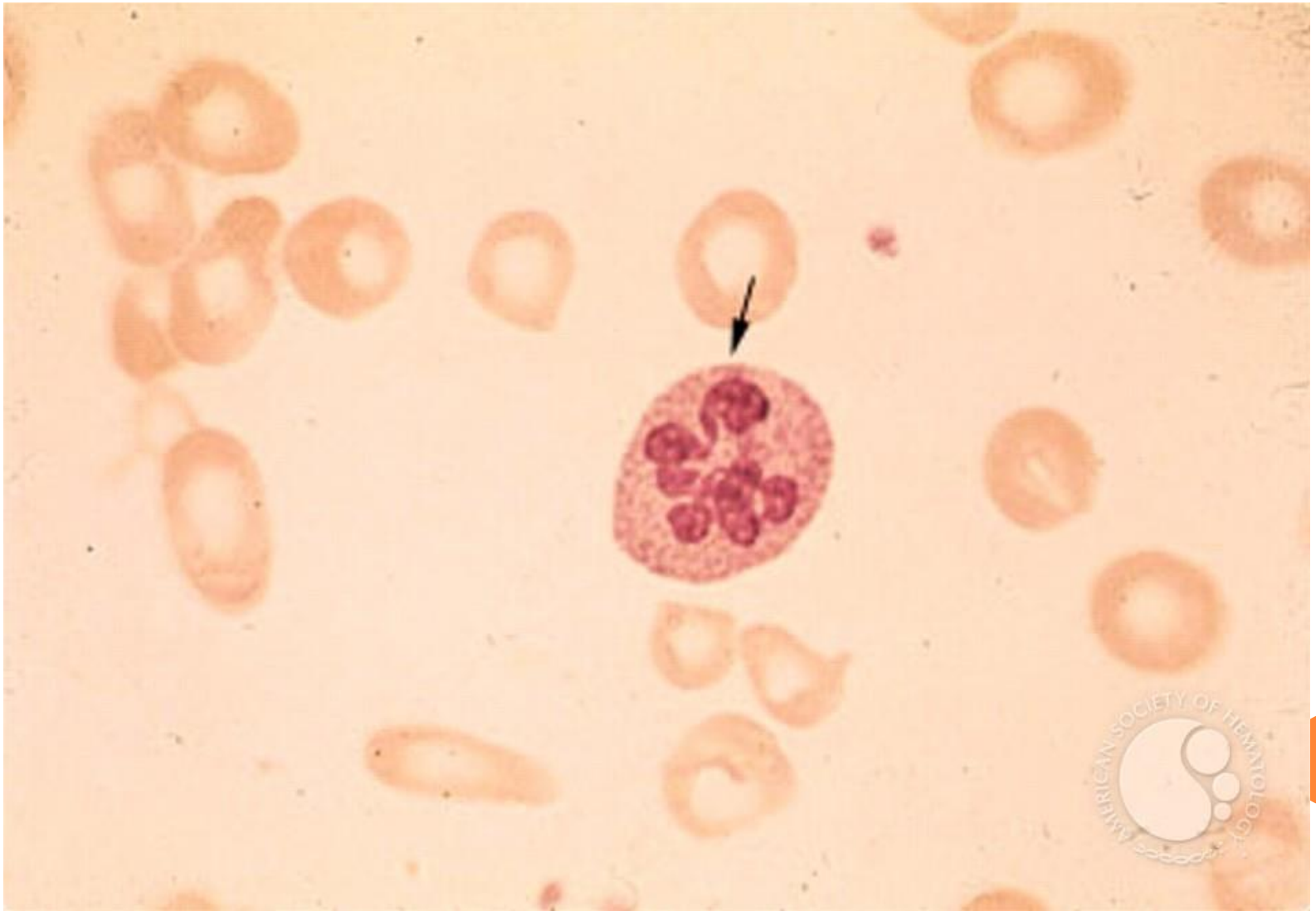

Normochromic normocytic anemia - 1.

Despite a reduction in the total number of red cells, the RBC indices are normal, and the cells have the typical area of central pallor without widespread variation in size and shape.

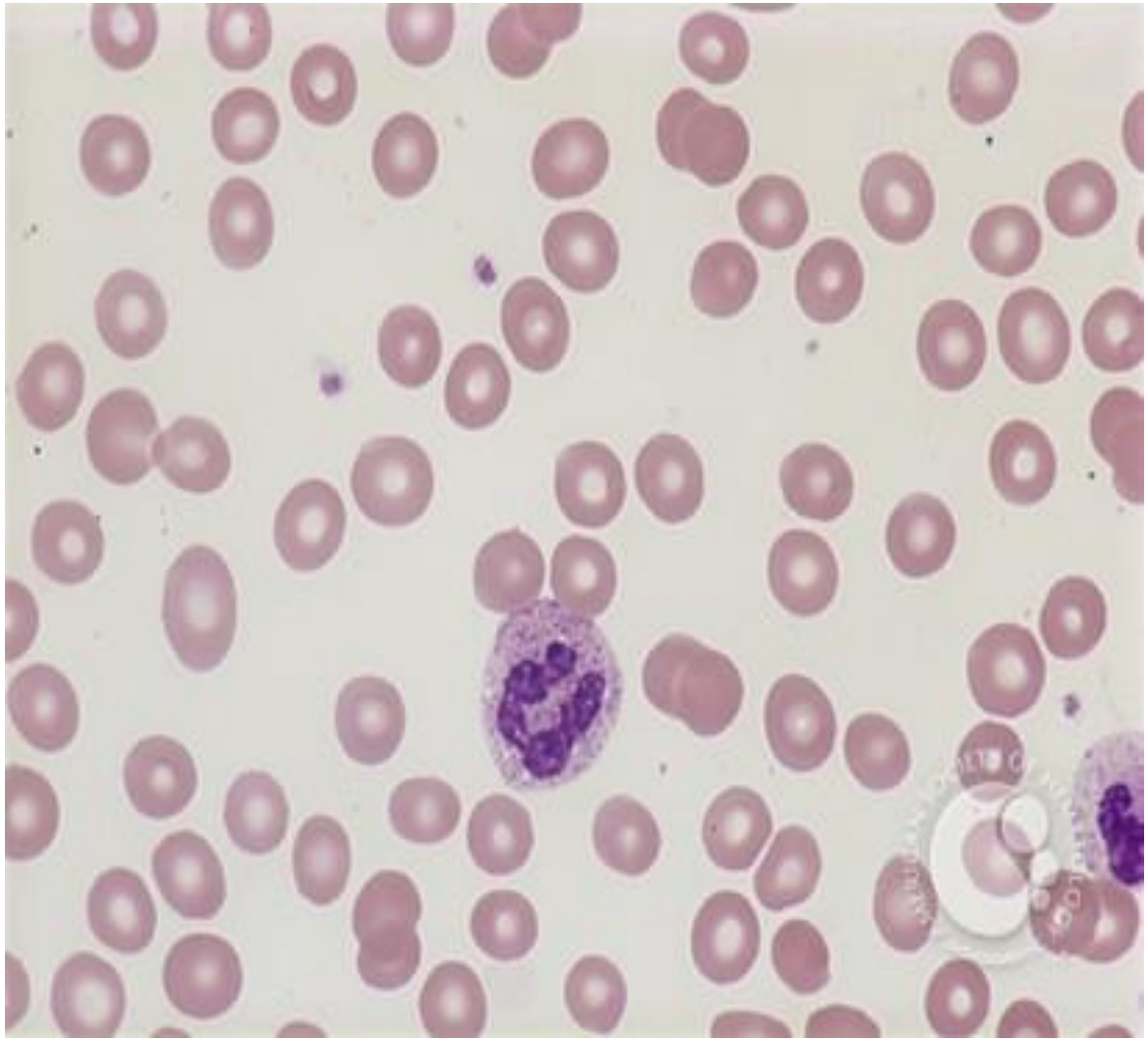

Microangiopathic hemolytic anemia secondary to artifical aortic valve malfunction - 2.

The smear is shown at higher magnification and demonstrates more clearly the marked schistocytosis.

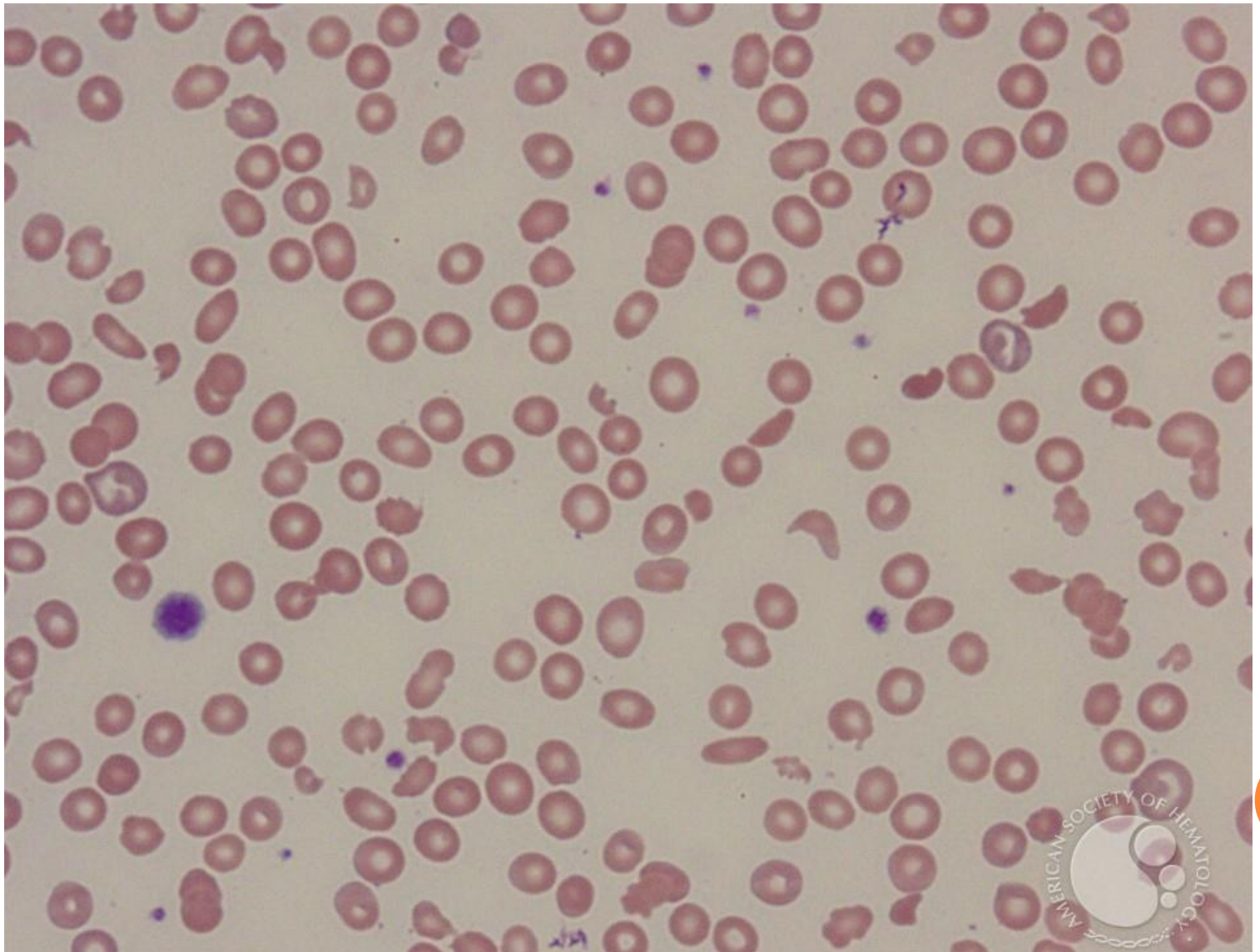

Refractory anemia with ringed sideroblasts and thrombocytosis (RARS-T) - Prussian blue iron stain - 1.

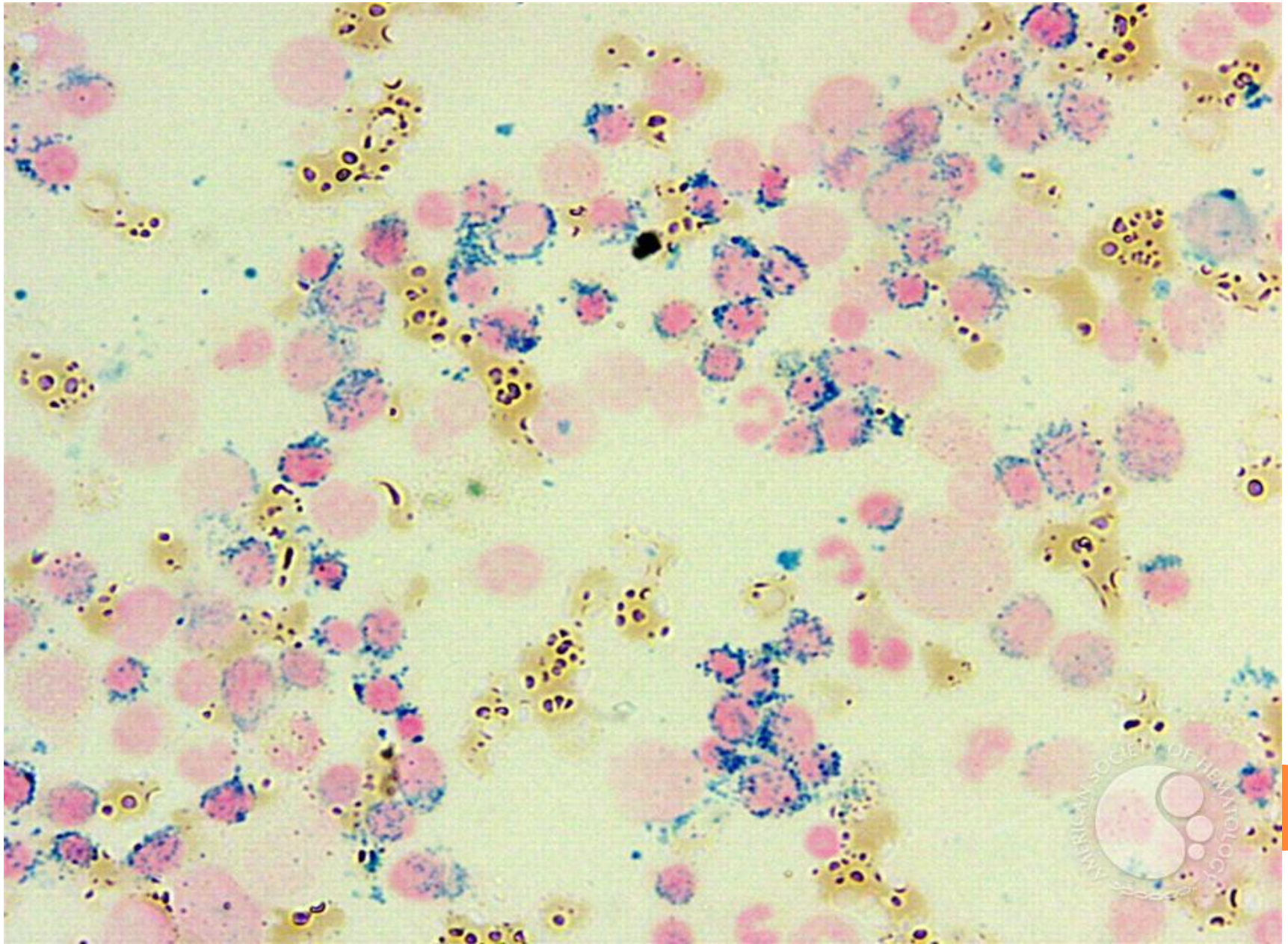
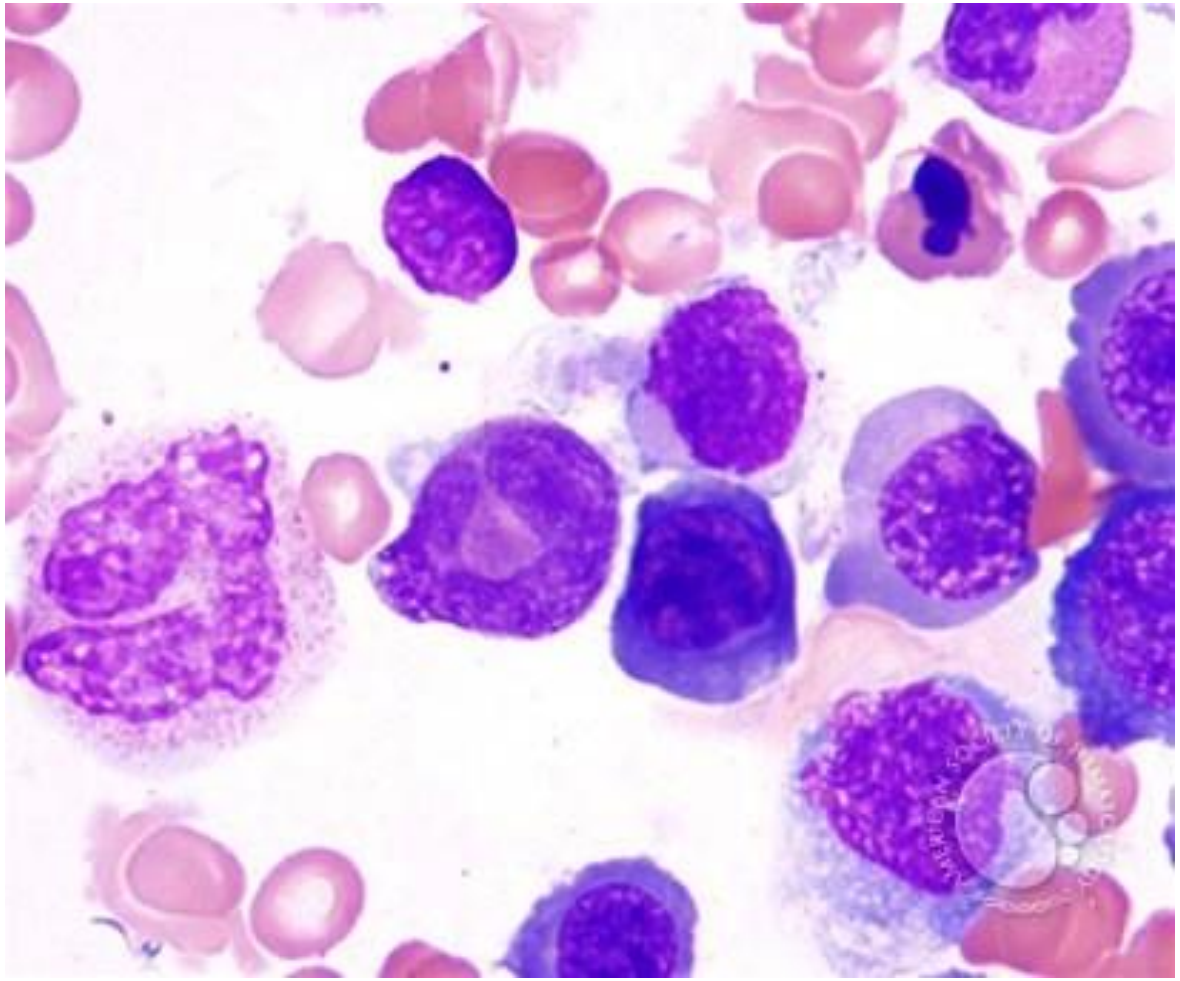
Megaloblastic Anemia Secondary to Pyrimethamine - 4.
Myeloid cells showing megaloblastic changes. Two giant bands are seen on the left of the field. One of these has features referred to as a "kissing band." In the right upper corner of the field a late erythroid form with nuclear budding is noted. 60X